

Original Research Article

Comparison of digital and conventional radiographic techniques

Daniele Lucca Longo¹
Ana Caroline Fumes¹
Daniela Silva Barroso de Oliveira¹
Katharina Morant Holanda de Oliveira¹
Priscilla Coutinho Romualdo¹
Francisco Wanderley Garcia de Paula e Silva¹
Erika Calvano Kuchler¹
Léa Assed Bezerra da Silva¹

Corresponding author:

Daniele Lucca Longo
Departamento de Odontopediatria.
Faculdade de Odontologia de Ribeirão Preto, Universidade de São Paulo
Avenida do Café, s/n – Monte Alegre
CEP 14040-904 – Ribeirão Preto – São Paulo – Brasil
E-mail: danielo.longo@usp.br

¹ Department of Pediatric Dentistry, School of Dentistry of Ribeirão Preto, University of São Paulo – Ribeirão Preto – SP – Brazil.

Received for publication: February 23, 2017. Accepted for publication: April 8, 2017.

Keywords:

dental radiograph;
pediatric dentistry;
primary tooth.

Abstract

Introduction and Objective: This study aimed to evaluate the correlation between conventional and digital radiographic methods in the measurement of periapical lesions in primary molars and compares the time used to obtain the radiographic images between both methods. **Material and methods:** This crossover study included children between 4 to 8-year-old with periapical lesion in primary mandibular molars. Fifteen molars were randomly assigned firstly to receive conventional or digital periapical radiograph during the steps of endodontic treatment. The time to obtain the radiographic image was evaluated in seconds and compared by the Mann-Whitney test. The periapical lesions measurement (mm²) were performed by the Image J software and the degree of correlation of measurement between both techniques was evaluated by the Spearman correlation test. Data was analyzed using the GraphPad Prism software ($\alpha = 0.05$). **Results:** A strong positive correlation between the measurement of lesions occurred on conventional methods in comparison with the measurement on digital methods ($r^2=0.778$; $p<0.0006$); however, the

time to obtain the radiographic images was shorter in the digital method ($p < 0.0001$). **Conclusion:** The digital method had a shorter amount of time to obtain the images and strong correlation for the lesions measurement in comparison to the conventional method. Therefore, the digital radiograph method is preferable for use in children.

Introduction

The periapical lesion occurs in teeth with pulp necrosis as result of a chronic aggression because of microorganisms inside the root canals or to chemical/physical injuries [16]. Radiographically, the lesion appears as a circumscribed radiolucent image on the periapical or interradicular area [12].

The correct diagnosis of periapical lesions by radiographs should be carefully done, once the diagnosis will define the treatment choice and prognosis. In addition, the radiographic examination is fundamental to assess the repair or the persistence of post-treatment periapical lesions [18, 22, 24]. The periapical radiograph is obtained from conventional radiographic films or via phosphorus plates and intraoral sensors. The conventional film was significantly less uncomfortable than five different types of digital intraoral sensors [17]. Therefore, this could be a factor that influences on the time to position the film or intraoral sensors in the oral cavity.

The literature lacks consensus on comparing the conventional and digital methods. Several authors find no statistical difference between the radiographic methods in the diagnosis of periapical lesions [3, 10], external radicular resorption [20], periodontal bone loss [2, 15], root perforation [25], and implant bone-interface [27]. On the other hand, other studies observe a difference in the detection of early periapical lesions, but no difference in the periapical lesions with greater dimensions [14] or that reached the cortical bone [23], and in the detection of misfitting at the implant-abutment interface [6].

Until now, *in vitro* studies showed no difference between the conventional and digital radiographic methods on the measurement of periapical lesions produced artificially [3, 10]. However, this model not faithfully reproduce the *in vivo* lesions, which are the result of a complex series of immunological, inflammatory, and infectious events with imprecise limits [26]. Therefore, this study aimed to evaluate the correlation between the conventional and digital radiographic methods in the measurement of periapical lesions in primary molars and to compare the time to obtain the radiographic images.

Material and methods

The study was approved by the Ethics Committee of the School of Dentistry of Ribeirão Preto – University of São Paulo (Process no. 42438814.4.0000.5419).

The patients were recruited and assisted at the Pediatric Clinic - Department of Pediatric Dentistry, School of Dentistry of Ribeirão Preto - University of São Paulo. The sample size calculation was performed based on earlier data from the Pediatric Clinic. The β value adopted was of 20% and the α was 5%, showing a total of 15 teeth.

Therefore, in this crossover study, the sample consisted of 15 children with periapical lesions in mandibular primary first or second molars ($n = 15$ primary molars) aged 4 to 8 years-old (mean 6.2 years); ten males and five females. The inclusion criteria were: enough dental crown height for rubber dam isolation, absence of periodontal involvement, location in mandible, and without prior endodontic treatment. The guardians of the patients were informed about the goals of the study and the Informed Consent Term was obtained.

The teeth were numbered in even and odd by simple randomization. The conventional radiograph was obtained firstly on the odd numbered teeth and the digital radiograph was taken next. On the even numbered teeth, the order of the radiographic techniques was reversed, starting with the digital radiograph, followed by the conventional radiograph.

The endodontic treatment protocol for teeth with pulp necrosis and periapical lesions was performed in accordance with techniques already established by the Department of Pediatric Dentistry of Ribeirão Preto – University of São Paulo [12]. In this study, the radiographs were obtained during the endodontic treatment. So, the patient was not exposed to any additional radiation.

Examination and X-ray evaluation

The periapical radiographs were performed according to the parallelism technique with a special positioner for endodontic procedures (Indusbello®,

Ind. Panel Dental Ltd., Londrina, Brazil). This apparatus standardizes the radiograph in the presence of rubber dam isolation.

For the conventional technique, periapical Ultraspeed disc® size 0 or 2 (Siemens, New York, USA) films were used, with 70 kV and 0.4 seconds of exposure. Briefly, the films were manually processed with a standardized processing time by the time-temperature method. For radiographic quantitative evaluation of periapical lesions, all conventional images were obtained with a Canon EOS 3Ti camera (Canon of Brazil Leimer, São Paulo, SP, Brazil), coupled to a wall-stand.

For the digital technique, it was used the Digora phosphorus plate (Soredex-Finndent, Orion Corporation, Helsinki, Finland), size 0 or 2, with 70 kV and 0.125 seconds of exposure. Then, the images were scanned by the VitaScan system (Dürr Dental of Brazil, Porto Alegre, RS, Brazil) with aid of the DBSWIN software.

Then, conventional and digital images were analyzed in the Image J 1.28 software (National Same patterns of Health, Bethesda, USA). Previously, the software was calibrated to compensate possible distortions by the mesio-distal measurement of the crown of each tooth evaluated with a drypoint compass. The radiolucent area corresponding to the periapical lesion was determined in mm² (figure 1). The evaluation was performed by a single investigator (intra-examiner Kappa = 0.96).

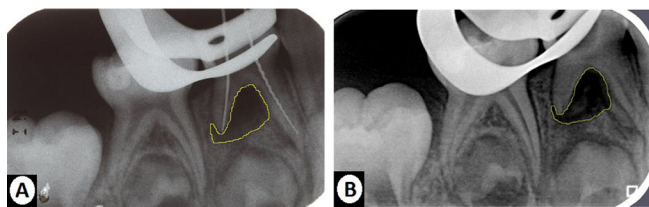


Figure 1 – Radiographic images showing the measurement of periapical lesions in Image J software. A) conventional radiograph; B) digital radiograph

Measurement of time to obtain radiographic image

The time to obtain the radiographic image was defined as the time used to take the radiograph and to process it, in seconds. This time was measured by one calibrated investigator, from the placing of the apparatus in the oral cavity to the triggering of the x-ray (radiographic taken time), in both

techniques. The processing time corresponds to the time of each technique for revelation and obtaining of the image for analysis.

Statistical analysis

All data were submitted to statistical analysis by Graph Pad Prism 5.0 software (Graph Pad Software Inc., San Diego, CA, USA).

Comparisons between the techniques, regarding the measurement of the periapical lesions (mm²) and the time to obtain radiographic image (seconds), were performed by the Mann-Whitney test. The level of significance adopted for all analyzes was 5%.

The Spearman test was used to evaluate the degree of correlation of the measurements of the periapical lesions, between both techniques, in all teeth. The strength of correlation was defined according to the value of the “Coefficient of Correlation (r^2)”, such as: 1: perfect; 0.7 a 0.9: strong; 0.4 a 0.6: moderate; 0.1 a 0.3: weak and 0: no correlation.

Results

The periapical lesion measurements were not statistically different in conventional and digital groups ($p=0.5615$). The median (Q1-Q3) was 10.66 mm² (4.591-19.99) in conventional method, while the median (Q1-Q3) was 6.712 mm² (4.110-16.93) in the digital method (figure 2).

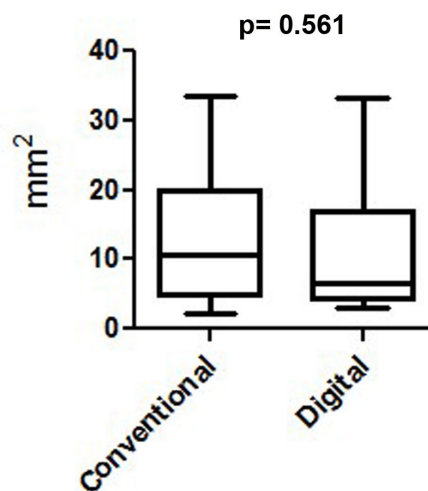


Figure 2 – Box plots for the periapical lesion measurements, in mm², on conventional and digital radiographic methods

In relation to the time for obtaining the radiographic images, the median (Q1-Q3) was 255.0 seconds (243.0-278.0) in conventional method, while the median (Q1-Q3) was 126.0 seconds (119.0-142.0) in the digital method, with statistically significant difference between groups ($p < 0.0001$) (figure 3).

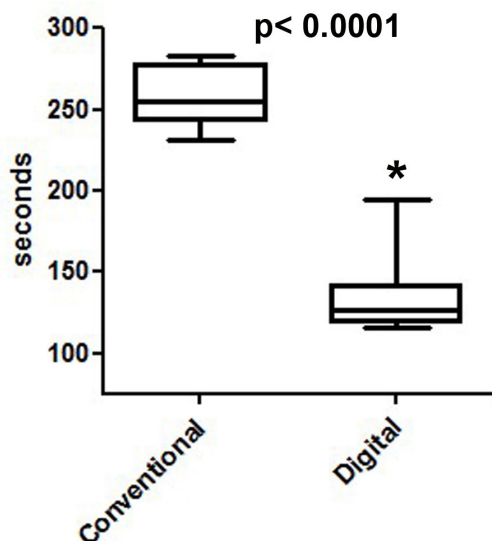


Figure 3 - Box plots for the time to obtain the radiographic images in seconds in conventional and digital methods. Statistically significant differences between the conventional and digital methods are indicated by asterisk (*)

A strong correlation occurred between the lesions measured in conventional and digital methods ($r^2 = 0.778$; $p < 0.0006$) (figure 4).

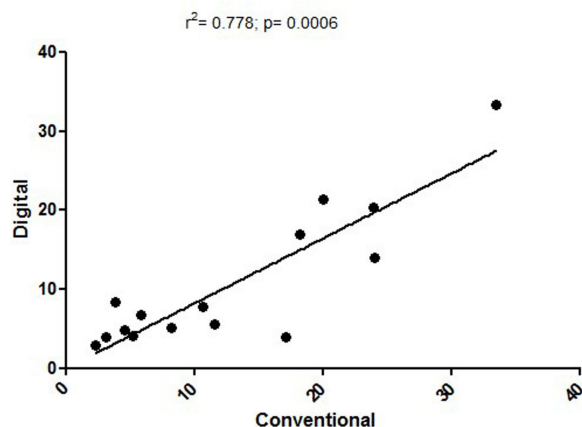


Figure 4 - Diagram showing strong correlation of periapical lesions measurements between the conventional and digital radiographic methods

Discussion

The results of this study proved that there was a strong positive correlation of lesion measurements between conventional and digital methods. These *in vivo* findings corroborate with other *in vitro* studies that also demonstrated no statistically significant difference between both radiographic methods in the detection of artificial lesions [3, 10].

The radiographic technique is very used to assess the repair or the persistence of the post-treatment periapical lesion [18, 22, 24]. Our results demonstrated that the two radiographic methods can be used in primary molars and may be alternated during different phases of the treatment.

However, the limitation of this clinical study is that it was not possible to figure out the real measurement of the periapical lesions. Thus, we cannot affirm whether some of the techniques underestimated or overestimated the measurements. On the other hand, in an animal model study previously conducted by our research group, it was observed that the conventional radiograph underestimated the size of post-treatment periapical lesions, in comparison to histological slices [8].

In addition, it is known that radiograph is a two-dimension method, which can be a limitation when evaluating the tooth and adjacent structures [1]. However, three-dimensional technique options such as computed tomography, for example, are not viable during the routine dental treatment, once the patient is exposed to large amounts of ionizing radiation, which are highly related to mutations in the DNA increasing the risk of cancer [7, 19].

The digital method took half of the time amount of that of conventional method. Still, the digital method has other advantages such as: the elimination of the chemical developing process, the immediate availability of the image, the image enhancement function (mostly changes of density and contrast), the small storage space needed, the use in teleradiology, the availability in multiple reprints, and the lower contamination of the environment [11, 13, 21, 28].

Specifically regards to child, the main advantage of using digital radiographic systems can be attributed to low exposure of patients to radiation [4, 9], since children are especially susceptible to radiation, present increased radiosensitivity, and have more number of years to be lived [5].

Therefore, although the techniques have been equivalent in relation to the measurement of periapical lesions, the digital method was faster to obtain the radiographic image than the conventional

method. In this sense, the use of digital method improves the monitoring of the periapical lesion regression in primary molars.

Conclusion

The digital method had a shorter time amount to obtain the images and strong correlation between the lesion measurements than the conventional method, and therefore, the digital radiograph method is preferable for using in children.

Acknowledgements

This study was partially supported by Grants from CAPES (PROEX scholarship to DLL).

References

1. Aghdasi MM, Asnaashari M, Aliari A, Fahimipour F, Soheilifar S. Conventional versus digital radiographs in detecting artificial voids in root canal filling material. *Iran Endod J.* 2011;6(3):99-102.
2. Ashwinirani SR, Suragimath G, Jaishankar HP, Kulkarni P, Bijjaragi SC, Sangle VA. Comparison of diagnostic accuracy of conventional intraoral periapical and direct digital radiographs in detecting interdental bone loss. *J Clin Diagn Res.* 2015;9(2):35-8.
3. Barbat J, Messer HH. Detectability of artificial periapical lesions using direct digital and conventional radiography. *J Endod.* 1998;24(12):837-42.
4. Borg E, Attaelmanan A, Grondahl HG. Subjective image quality of solid-state and photostimulable phosphor systems for digital intra-oral radiography. *Dentomaxillofac Radiol.* 2000;29(2):70-5.
5. Brenner DJ, Elliston CD, Hall EJ, Berdon WE. Estimates of the cancer risks from pediatric CT radiation are not merely theoretical: comment on "point/counterpoint: in x-ray computed tomography, technique factors should be selected appropriate to patient size. against the proposition". *Med Phys.* 2001;28:2387-8.
6. Cançado Oliveira BF, Valerio CS, Jansen WC, Zenóbio EG, Manzi FR. Accuracy of Digital versus conventional periapical radiographs to detect misfit at the implant-abutment interface. *Int J Oral Maxillofac Implants* 2016;31(5):1023-9.
7. Cerqueira EM, Meireles JR, Lopes MA, Junqueira VC, Gomes-Filho IS, Trindade S et al. Genotoxic effects of X-rays on keratinized mucosa cells during panoramic dental radiography. *Dentomaxillofac Radiol.* 2008;37(7):398-403.
8. Diangelis AJ, Andreasen JO, Ebeleseder KA, Kenny DJ, Trope M, Sigurdsson A et al. International Association of Dental Traumatology guidelines for the management of traumatic dental injuries: 2. Avulsion of permanent teeth. Hebrew edition. Refuat Hapeh Vehashinayim (1993). 2014;31(2):57-68.
9. Erten H, Akarslan ZZ, Topuz O. The efficiency of three different films and radiovisiography in detecting approximal carious lesions. *Quintessence Int.* 2005;36(1):65-70.
10. Grondahl HG, Wenzel A, Borg E, Tammissalo E. An image plate system for digital intra-oral radiography. *Dent Update.* 1996;23(8):334-7.
11. Huda W, Rill LN, Benn DK, Pettigrew JC. Comparison of a photostimulable phosphor system with film for dental radiology. *Oral Surg Oral Med Oral Pathol Oral Radiol Endod.* 1997;83(6):725-31.
12. Ito IY, Junior FM, Paula-Silva FW, Silva LAB, Leonardo MR, Nelson-Filho P. Microbial culture and checkerboard DNA-DNA hybridization assessment of bacteria in root canals of primary teeth pre- and post-endodontic therapy with a calcium hydroxide/chlorhexidine paste. *Int J Paediatr Dent.* 2011;21(5):353-60.
13. Jacobsen JH, Hansen B, Wenzel A, Hintze H. Relationship between histological and radiographic caries lesion depth measured in images from four digital radiography systems. *Caries Res.* 2004;38(1):34-8.
14. Kullendorff B, Nilsson M, Rohlin M. Diagnostic accuracy of direct digital dental radiography for the detection of periapical bone lesions: overall comparison between conventional and direct digital radiography. *Oral Surg Oral Med Oral Pathol Oral Radiol Endod.* 1996;82(3):344-50.
15. Leonardi Dutra K, Haas L, Porporatti AL, Flores-Mir C, Nascimento Santos J, Mezzomo LA et al. Accuracy of cone-beam computed tomography and conventional radiography on apical periodontitis: a systematic review and meta-analysis. *J Endod.* 2016;42(3):356-64.
16. Marton IJ, Kiss C. Protective and destructive immune reactions in apical periodontitis. *Oral Microbiol Immunol.* 2000;15(3):139-50.

17. Matzen LH, Christensen J, Wenzel A. Patient discomfort and retakes in periapical examination of mandibular third molars using digital receptors and film. *Oral Surg Oral Med Oral Pathol Oral Radiol Endod.* 2009;107(4):566-72.
18. Mead C, Javidan-Nejad S, Mego ME, Nash B, Torabinejad M. Levels of evidence for the outcome of endodontic surgery. *J Endod.* 2005;31(1):19-24.
19. Memon A, Godward S, Williams D, Siddique I, Al-Saleh K. Dental x-rays and the risk of thyroid cancer: a case-control study. *Acta Oncol.* 2010;49(4):447-53.
20. Mesgarani A, Haghanifar S, Ehsani M, Yaghub SD, Bijani A. Accuracy of conventional and digital radiography in detecting external root resorption. *Iran Endod J.* 2014;9(4):241-5.
21. Molander B, Grondahl HG, Ekestubbe A. Quality of film-based and digital panoramic radiography. *Dentomaxillofac Radiol.* 2004;33(1):32-6.
22. Ng YL, Mann V, Rahbaran S, Lewsey J, Gulabivala K. Outcome of primary root canal treatment: systematic review of the literature – part 1. Effects of study characteristics on probability of success. *Int Endod. J* 2007;40(12):921-39.
23. Paurazas SB, Geist JR, Pink FE, Hoen MM, Steiman HR. Comparison of diagnostic accuracy of digital imaging by using CCD and CMOS-APS sensors with E-speed film in the detection of periapical bony lesions. *Oral Surg Oral Med Oral Pathol Oral Radiol Endod.* 2000;89(3):356-62.
24. Saraf PA, Kamat S, Puranik RS, Puranik S, Saraf SP, Singh BP. Comparative evaluation of immunohistochemistry, histopathology and conventional radiography in differentiating periapical lesions. *J Conserv Dent.* 2014;17(2):164-8.
25. Takeshita WM, Chicarelli M, Iwaki LC. Comparison of diagnostic accuracy of root perforation, external resorption and fractures using cone-beam computed tomography, panoramic radiography and conventional & digital periapical radiography. *Indian J Dent Res.* 2015;26(6):619-26.
26. Tirrell BC, Miles DA, Brown Jr CE, Legan JJ. Interpretation of chemically created lesions using direct digital imaging. *J Endod.* 1996;22(2):74-8.
27. Vidor MM, Liedke GS, Vizzotto MB, da Silveira HL, da Silveira PF, Araujo CW et al. Imaging evaluating of the implant/bone interface-an in vitro radiographic study. *Dentomaxillofac Radiol.* 2017 [Epub ahead of print].
28. Visser H, Rodig T, Hermann KP. Dose reduction by direct-digital cephalometric radiography. *Angle Orthod.* 2001;71(3):159-63.