

Case Report Article

Jaw osteonecrosis after dental implants associated with oral bisphosphonates – case report of resection of mandible

Paola Fernanda Cotait de Lucas Corso¹
Sara Regina Toderó²
Aline Monise Sebastiani¹
Leandro Eduardo Kluppel³
Nelson Luis Barbosa Rebellato²
Delson João da Costa²
Rafaela Scariot¹

Corresponding author:

Rafaela Scariot
Universidade Positivo
Rua Professor Pedro Viriato Parigot de Souza, 5.300 – Campo Comprido
CEP 81280-330 – Curitiba – Paraná – Brazil
E-mail: rafaela_scariot@yahoo.com.br

¹ Department of Oral and Maxillofacial Surgery, Positivo University – Curitiba – PR – Brazil.

² Department of Oral and Maxillofacial Surgery, Federal University of Parana – Curitiba – PR – Brazil.

³ Department of Anatomy, Federal University of Parana – Curitiba – PR – Brazil.

Received for publication: April 4, 2017. Accepted for publication: May 11, 2017.

Keywords:

bisphosphonates;
osteonecrosis; jaw.

Abstract

Introduction: Osteonecrosis of the jaw is associated with defects in vascularization and with the use of oral bisphosphonates. Osseous exposition and infection may occur. Recommended treatment is variable, from antibiotic medication, bony decortication to resections of the mandible in severe cases. Reconstruction of mandible, in cases of resections is essential for maintaining esthetic profile and adequate form and function. **Objective:** To report a case about the dangers of oral bisphosphonates in association with invasive procedures such as dental implants **Case report:** Female patient, 64 years-old, with osteonecrosis of the jaw caused by use of oral bisphosphonates after rehabilitation with dental implants. She had an edentulous and atrophic mandible and poor healthy. After diagnosis, partial resection of the jaw was performed together with the reconstruction with titanium plate, with no success. Then, iliac bone graft fixed by plates and screws was attempted, again with no success. **Conclusion:** Despite of the small number of cases of osteonecrosis associated with oral bisphosphonate reported in the literature, a simple implant surgery could result in adverse consequences if the use of this medication were overlooked in the anamnesis.

Introduction

Bisphosphonates are nonmetabolized analogues of endogenous pyrophosphate that bind strongly to the bone mineral, hydroxyapatite, and are capable of localizing to bone and inhibiting osteoclastic function. The key pharmacological action of bisphosphonates in clinical use is inhibition of bone resorption. The exact mechanism of action of this bisphosphonate-mediated osteoclast inhibition has not been completely elucidated. On one hand, it is hypothesized that bisphosphonates are released by invasive dental treatment, such as tooth extractions or implant placement, with possible subsequent direct toxicity to the surrounding soft tissue or periosteum; on the other hand, evidence supports the hypothesis that bisphosphonate associated with osteonecrosis of the jaw is a special type of osteomyelitis [18, 19, 21].

Intravenous bisphosphonates are used to reduce bone pain, hypercalcemia of malignancy and skeletal complications in patients with multiple myeloma, lung, breast, and other cancers. Oral bisphosphonates are used to treat systemic osteoporosis, Paget's disease, and osteogenesis imperfect [3]. Bisphosphonate medication associated with osteonecrosis of the jaw is a current topic in the recent papers [8]. Marx [16], in 2003, was the first author to report pain and exposure of the bone in the mandible and maxilla in patients who used bisphosphonates. Researchers estimated the incidence of bisphosphonate associated with osteonecrosis of the jaw range from 0.8% to 12% for patients receiving intravenous formulations [3]. In a study made by Lo *et al.* [12], in 2009, the osteonecrosis in patients exposed to oral bisphosphonates occurred in 1 of 952 survey respondents (minimum prevalence of 1 in 1,537 of the entire mailed cohort).

The disease classification is divided into stages according to characteristics present in the people affected. Patients at risk are asymptomatic patients with no clear necrotic bone, who have been treated with intravenous or oral bisphosphonates. It might be considered to have bisphosphonate related osteonecrosis of the jaws if 3 characteristics are present: 1. Current or earlier treatment with a bisphosphonate; 2. Exposed bone in the maxillofacial region that has persisted for more than 8 weeks; 3. No history of radiation therapy of the jaws. Cases of osteonecrosis caused by bisphosphonates were divided into stages: Stage 0 - Patients with no clinical evidence of necrotic

bone, but with nonspecific symptoms or clinical and radiographic findings; Stage 1 - exposed and necrotic bone in patients who are asymptomatic and have no evidence of infection; Stage 2 - exposed and necrotic bone in patients with pain and clinical evidence of infection; Stage 3 - exposed and necrotic bone in patients with pain, infection, and that may present: pathologic fracture, extraoral fistula, oral, antral or nasal communication, osteolysis extending to the inferior border of the mandible or sinus floor [22].

Treatment strategies should be in accordance with disease stage. Patients at risk: not requiring any treatment, however these patients should be informed of the risks, as well as the signs and symptoms of this disease process. Stage 0: provide symptomatic treatment, and take care of other local factors, such as caries and periodontal disease. Systemic management can include the use of medication for chronic pain and the control of infection with antibiotics, when indicated. Stage 1: No surgical treatment is indicated, these patients benefit from the use of oral antimicrobial rinses, such as 0.12% chlorhexidine. Stage 2: these patients benefit from antibiotic therapy and oral antimicrobial rinses. In some refractory cases, patients might require combination of antibiotic therapy, long term antibiotic maintenance, or a course of intravenous antibiotic therapy. Stage 3: these patients benefit from debridement, including resection, of all necrotic bone, combined with antibiotic therapy, which might offer long-term palliation, with resolution of acute infection and pain [22].

When it is necessary debridement and resection because the loss of mandibular continuity, there is significant functional disability, cosmetic deformity, and pathological impairment [11]. The need for reconstruction of the mandible is obvious, because accounts for the patients' profile and serves as a support for the tongue, allowing mastication, deglutition, and phonation. However, the mandible is difficult to reconstruct. It is not only highly contoured and stress bearing, but in oral cavity it is covered superficially only by mucosa [6]. Different operative techniques are used to reconstruct the defects, but every method that was chosen must fulfill three main goals: restoration of continuity, restoration and maintenance of form and body, and restoration of function and esthetics [1].

This paper reports the case of an elderly patient who used oral bisphosphonates and developed osteonecrosis of the jaw after a dental implant surgery, with a poor prognosis of treatment attempts.

Case report

A 64-year-old female patient was referred in February 2007 to the Oral and Maxillofacial Surgery Service, Federal University of Paraná at Curitiba, Brazil, with pain in mandible. The patient reported she underwent dental implant surgery in the anterior region of mandible in 2004, which were later lost. In 2005, the patient referred listened some noise in her mandible when she was eating, followed by pain in this region. From this day on, she searched many services, with no success.

During the anamnesis, the patient mentioned the use of Alendronate® for approximately five years

to treat osteoporosis. At the extraoral examination, we observed active suppuration from a fistulous tract in the right side of the mental region. The region presented with a considerable swelling and the patient related pain. At the maximum mouth opening, the mandible shifted to the right side. At the intraoral examination, the patient had no mandibular teeth and she reported not using the prosthesis anymore. It was possible to observe some exposed osseous sequestration in oral cavity. Radiographic examinations showed a mixed sclerotic pattern and a fracture in the midline of the mandible (figure 1).

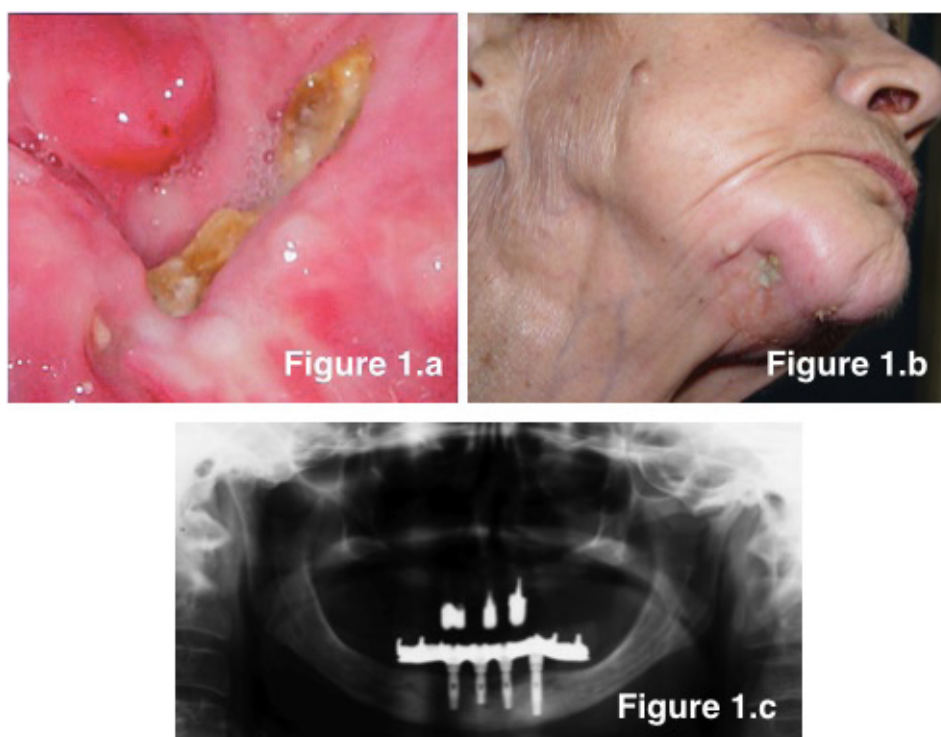


Figure 1 - a) Exposed osseous sequestration; b) Initial view: extraoral fistulous tract; c) Initial panoramic radiograph showing dental implants

After the incisional biopsy, the diagnosis suggested a chronic osteomyelitis of the mandible, because of the signs of the chronic inflammation with the medullary fibrosis. The use of bisphosphonates was associated as a possible cause of osteonecrosis.

Antibiotic treatment in combination with surgical procedures was the protocol treatment of the institution. Patient received an antibiotic

regimen consisting of Cephalexin 500 mg, every six hours, for thirty days. Because of the pathological condition, midline fracture, edentulous and atrophic mandible, and the extension of pathology, the treatment of choice was segmental resection of the anterior region of mandible and reconstruction with titanium bridging plate contoured according to the shape of mandible (figure 2).

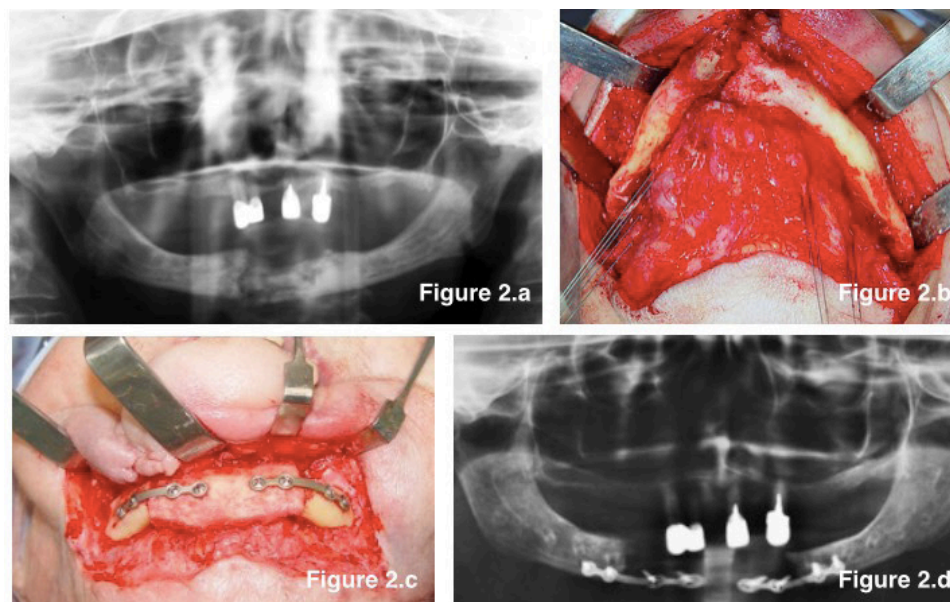


Figure 2 - a) Radiograph showing a mixed sclerotic pattern and a fracture in the midline of the mandible; b) The fracture and necrotic area exposed during the surgery; c) Iliac bone graft fixed by plates and screws; d) Immediate post-operative radiograph

The patient's health was poor, she was quite thin and needed special care, proper preoperative nursing besides psychological consolation. For this procedure, the patient was submitted to many examinations, mainly because of her weight: 70.54 pounds. The patient was instructed by the nutritionist and endocrinologist and gained 8.81 pounds before the surgery procedure.

In April 2007, the surgery was done. An extraoral approach was executed. After carefully dissection, the mandible was exposed. It was possible to observe the line of fracture and infected bone around it. In general, margins of at least 10mm beyond all clinically clear pathological mass were obtained during the surgery. The reconstruction

plate (Neortho System®, Curitiba-PR/Brazil) was modeled, positioned, and fixed to the ends of the remaining mandible segments (figure 3). The plate was wrapped by muscle. The clinical incision was closed at different layers. The specimen was fixed in 10% formalin and submitted to microscopic evaluation, which confirmed the results obtained in the first biopsy. The position of the plate was verified with a panoramic radiograph. The patient had no shifting in her maximum mouth opening. After one week, an intraoral point of exposure of the plate on the symphyseal region occurred in the same place that infected bone was exposed before surgery. Irrigations of the region were made with povidine.

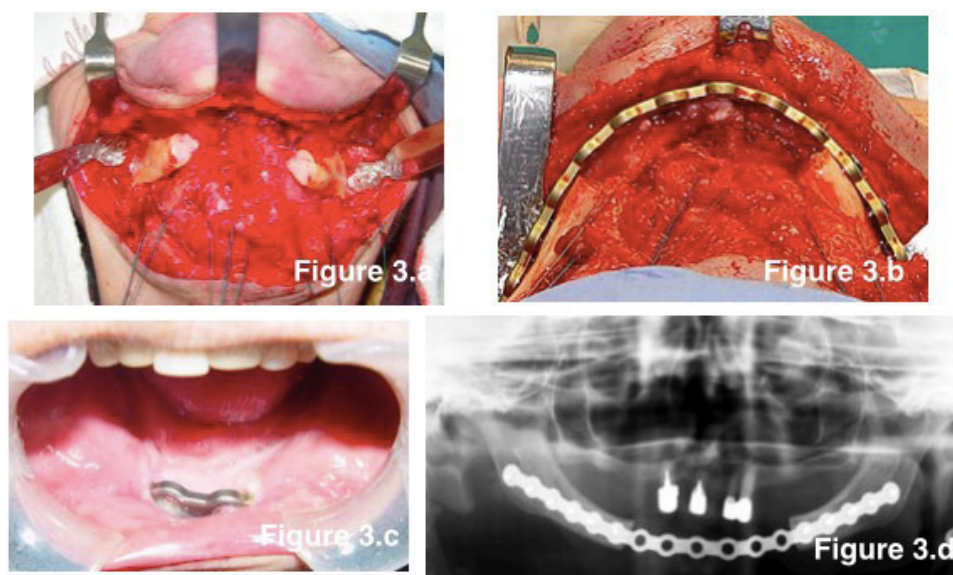


Figure 3 - a) Resection of the necrotic bone; b) Reconstruction plate after bone debridement; c) Intraoral exposure of the plate; d) Immediate post-operative radiograph

In March 2008, one year after surgery, the patient presented an extraoral point of active suppuration in mental region. She reported moderate pain in the right side of the jaw. Antibiotic and analgesics were prescribed. The treatment attempts were unsuccessful, and eight months later, the patient evolves with extraoral exposure of the plate.

A new treatment was planned for the patient, together with the plastic surgery team, at two surgical times. First, the plate was removed followed by debridement of infection by a multidisciplinary team composed by plastic surgeon and oral and maxillofacial surgeon. Second, a month later, an autogenous grafting from the iliac bone was removed by the orthopedic medical staff. The block was fixed in the jaw with plates Neortho System®. After some weeks, exposure of the graft occurred intraorally and extraorally with constant drainage point. The radiographic examination showed no consolidation of the graft, and two screws were lost in the right side of the jaw. The surgeons decided to remove the graft and no reconstruction was performed at that moment. The intraoperative time occurred with no intercurrents. In the end of the procedure, the anesthesiologist placed a nasogastric tube to ensure the nutritional support to the patient. The patient had an episode of vomiting and bronchial aspiration over the content of the diet, leading to a pneumothorax, resulting in multiple organ failure and death.

Discussion

Current literature includes only a small number of cases of osteonecrosis of the jaw following surgery in oral cavity of patients taking oral bisphosphonates [21]. The American Dental Association published special recommendations about care with placement of dental implants or guided bone regeneration that involves risk of developing osteonecrosis in patients who uses or had taken oral bisphosphonates. The recommendations of The American Association of Oral and Maxillofacial Surgeons do not contraindicate the surgery of dental implants in patients who have been taking bisphosphonates orally for under three years if their had no other risk factors such as medication with corticosteroids or advanced age. In cases who the patient has been taking the drug for three years, it is recommended to cease medication for a minimum of three months before any type of surgical intervention, and in the case of dental implants, it is recommended to wait three months before administrating the drug again [5]. Ruggiero *et al.* [22] also believed that the time of taking bisphosphonates was a significant risk to osteonecrosis because other factors as systemic/local features and potency of bisphosphonates may raise the incidence rate of the osteonecrosis. Shin *et al.* [23] described that implant treatments have increased markedly also in elderly persons. The numbers of patients who have been treated

with bisphosphonates or continue to use them for treatment of osteoporosis is rising. As a result, the risk of oral bisphosphonate-related osteonecrosis of the jaw increases after implant placement. The more powerful potency of bisphosphonates and the longer period of taking also increase the chance of osteonecrosis.

Fernández *et al.* [7], in 2009, observed through a literature review that six patients had osteonecrosis of the jaw caused by bisphosphonates related with dental implants: five were women (all over 50 years of age); 3 with osteoporosis and 2 with osteopenia. One patient was treated with zoledronic acid; 3 with alendronate, 1 with etidronate disodium and another with risedronate.

In other study, 44 dental implants were placed (26 patients who had taken bisphosphonates for less than 3 years and 18 patients who had taken the medication for more than 3 years). Of the 26 individuals of first group, 7 were associated with osteonecrosis of the jaw and 6 implants were lost (5 in the jaw); of the last 18 individuals, 14 suffered osteonecrosis of the jaw and 4 implants were lost (the 4 located in the jaw) [7].

Tam *et al.* [25], in 2014, present six cases of jaw osteonecrosis that might have occurred because the patients had taken nitrogen containing bisphosphonates via oral and/or intravenous route before placing dental implants. Two of these patients had taken only oral bisphosphonate and the authors state that unusual jaw necrosis after dental implants might be related with oral and/or intravenous bisphosphonates. The authors also described that the keys to successful healing are wide resection of necrotic bone, collagen graft and primary closure. The growth in the number of treatments with dental implants has brought also a great argumentation in the number of complications related with them. Advanced osteomyelitis could be fracture of the jaw, mainly if the mandible is edentulous and atrophic [28].

The treatment of osteonecrosis of the jaw depends on the severity and stage of the osteonecrosis, current concepts vary from conservative approaches with antimicrobial rinsing and oral antibiotics to radical surgery. The concept is characterized by surgical resection of the entire necrotic bone followed by conscientious smoothing of sharp bone edges, and then wound closure [26]. Most of resections are immediately reconstructed with a rigid titanium plate so that secondary infection is controlled; another approach consists of installing the plate only after the recipient site has healed and is infection free. Bone graft reconstructions

are rarely needed, but can be also an alternative [17]. Madsen and Hang [14] believe that biologic and biomechanical problems are associated with elderly population. Reduction in blood flow, change in bone quality and loss of the buttressing effects associated with diminished bone height are examples of these modifications. For this reason, it is necessary to use special fixation material and techniques in atrophic edentulous mandible.

Our treatment of choice was the resection of mandibular symphysis followed by reconstruction. The decision was based on the history of patient: dental implants, osteomyelitis, fracture of atrophic and edentulous mandible, and poor systemic conditions. The use of rigid internal fixation (reconstruction system) increased stability during the repair of this surgery reestablishing bone continuity, functionality, and esthetics [13, 14].

One of the problems related to reconstruction of these plates is the exposure of the plates in the oral cavity [2, 4, 10, 13, 15]. Lopez *et al.* [13] affirmed that the correct alternative to solve such problems is a new flap.

Hanasono *et al.* [9] reported that their experience following segmental mandibulectomy with microvascular free flap reconstruction in patients with advanced osteonecrosis is an effective reconstructive option in patients with stage 3. The success rate of this treatment is high according to the authors, but complications are frequent.

We decided to try a different attempt because of persistent exposure and recurrent infections. Remove the plate and perform a correct debridement of the jaw awaiting proper bone healing and stability to realize an autogenous iliac bone graft. Unfortunately, after the surgery of autogenous iliac bone graft, some signs of non-integration made the surgeons remove all the bone graft, but the patient's systemic conditions and an unexpected medical complication led the patient to death.

After the patient's death, the family reported that the patient used to smoke, which was never reported. In a study made by Rodriguez-Argueta *et al.* [20], they discussed how the cigarette components affected the bone vascularization, the nicotine is a potent vasoconstrictor that reduces blood flow and nutrient delivery to healing sites, causing tissue glucose reduction and acidosis. The carbon monoxide also reduces the oxygen-carrying capacity of erythrocytes, and hydrogen cyanide causes tissue hypoxia [20, 24, 27]. Additionally, the very poor systemic health did not allow an adequate treatment and she did not respond to several attempts.

Conclusion

Despite of the small number of cases of osteonecrosis of the jaw associated with the use of oral bisphosphonate after implant surgery reported in the literature, the use of this medication should be carefully analyzed during the patient's medical history and considered in treatment planning, especially when associated with other risk factors. The use of bisphosphonate put the individual at high risks. In this case report, a simple dental implant surgery became a source of weakness for the patient. Lack of knowledge about the risk of bisphosphonates together with other risk factors such as the patient's poor systemic conditions led to years of failed rehabilitation attempts. Therefore, a detailed anamnesis, explaining to patients the importance of giving correct answers, and attention to every medication in use, based on scientific evidences, is still the best way to prevent complications in dentistry.

References

1. Alonso HJ, Fernandez SJ, Rubio BP, Diaz GFJ, Gil-Diez UJL, Monie GF et al. Primary mandibular reconstruction with bridging plates. *J Craniomaxillofac Surg.* 1994;22(1):43-8.
2. Arden RI, Rachel JD, Marks S, Dang K. Volume-length impact of lateral jaw resections on complication rates. *Arch Otolaryngol Head Neck Surg.* 1999;125(1):668-72.
3. Bao-Thy G, Christopher A, Katherine F, Richard AK. Outcomes of placing dental implants in patients taking oral bisphosphonates: a review of 115 cases. *J Oral Maxillofac Surg.* 2008;66(2):223-30.
4. Blackwell KE, Lacombe V. The bridging mandibular reconstruction plate revisited. *Arch Otolaryngol Head Neck Surg.* 1999;125(9):988-93.
5. Carralero JMM, Mino PP, Fernández PR, Murcia IMM, Gambín MCM, Guirado JLC. Dental implants in patients treated with oral bisphosphonates. A bibliographic review. *Med Oral Patol Oral Cir Buc.* 2010;15(1):65-9.
6. Dumbach J, Rodemer H, Spitzer WJ, Steinhäuser EW. Mandibular reconstruction with cancellous bone, hydroxylapatite and titanium mesh. *J Craniomaxillofac Surg.* 1994;22(3):151-5.
7. Fernández AJF, Martínez JB, Diago MP, Bagán JV. Bisphosphonates and dental implants: current problems. *Med Oral Patol Oral Cir Bucal.* 2009;14(7):355-60.
8. Gender T, Obwegeser JA, Zemann W, Gratz KW, Jacobsen C. Malignancy mimicking bisphosphonate-associated osteonecrosis of the jaw: a case series and literature review. *Oral Surg Oral Med Oral Radiol.* 2014;117(1):32-6.
9. Hanasono MM, Militsakh ON, Richmon JD, Rosenthal EL, Wax MK. Mandibulectomy and free flap reconstruction for bisphosphonate-related osteonecrosis of the jaws. *JAMA Otolaryngol Head Neck Surg.* 2013;139(11):1135-42.
10. Klotch D, Gal T, Gal R. Assessment of plate use for mandibular reconstruction: Has changing technology made difference? *Otolaryngol Head Neck Surg.* 1999;121(4):388-92.
11. Li Z, Zhao Y, Yao S, Zhao J, Yu S, Zhang W. Immediate reconstruction of mandibular defects: a retrospective report of 242 cases. *J Oral Maxillofac Surg.* 2007;65(5):883-90.
12. Lo JC, O'Ryan FS, Gordon NP, Yang J, Hui RL, Martin D et al. Prevalence of osteonecrosis of the jaw in patients with oral bisphosphonate exposure. *J Oral Maxillofac Surg.* 2010;68(2):243-53.
13. Lopez R, Dekeister C, Sleiman Z, Paoli JR. Mandibular reconstruction using the titanium functionally dynamic bridging plate system: a retrospective study of 34 cases. *J Oral Maxillofacial Surg.* 2004;62(4):421-6.
14. Madsen MJ, Hang RH. A biomechanical comparison of 2 techniques for reconstruction atrophic edentulous mandible fracture. *J Oral Maxillofac Surg.* 2006;64(3):457-65.
15. Marx RE. Mandibular reconstruction. *J Oral Maxillofac Surg.* 1993;51(5):466-79.
16. Marx RE. Pamidromate (Aredia) and zoledronate (Zometa) induced avascular necrosis of the jaws: a growing epidemic. *J Oral Maxillofac Surg.* 2003;61(9):1115-7.
17. Marx RE. Reconstruction of defects caused by bisphosphonate-induced osteonecrosis of the jaws. *J Oral Maxillofac Surg.* 2009;67(5):107-19.
18. Mawardi H, Giro G, Kajiya M, Ohta K, Almazrooa S, Alshwaimi E et al. A role of oral bacteria in bisphosphonate-induced osteonecrosis of the jaw. *J Dent Res.* 2011;90(11):1339-45.

19. Rodan A, Fleisch HA. Bisphosphonates: mechanisms of action gideon. *J Clin Invest.* 1996;97(12):2692-6.
20. Rodriguez-Argueta OF, Figueiredo R, Valmaseda-Castellon E, Gay-Escoda E. Postoperative complications in smoking patients treated with implants: a retrospective study. *J Oral Maxillofac Surg.* 2011;69(8):2152-7.
21. Ruggiero SL. Osteonecrosis of the jaws associated with the use of bisphosphonates: a review of 63 cases. *J Oral Maxillofac Surg.* 2004;62(5):527-34.
22. Ruggiero SL, Dodson TB, Assael LA, Landesberg R, Marx RE, Mehrotra B et al. American Association of Oral and Maxillofacial Surgeons position paper on bisphosphonate-related osteonecrosis of the jaw. *J Oral Maxillofac Surg.* 2009;67(5):2-12.
23. Shin EY, Kwon YH, Herr Y, Shin SI, Chung JH. Implant failure associated with oral bisphosphonate-related osteonecrosis of the jaw. *J Periodont Implant Sci.* 2010;40(02):90-5.
24. Sorensen LT, Jorgensen S, Petersen LJ, Hemmingsen U, Bülow J, Loft S et al. Acute effects of nicotine and smoking on blood flow, oxygen, and aerobic metabolism of the skin and subcutis. *J Surg Res.* 2009;152(2):224-30.
25. Tam Y, Kar K, Nowzari H, Cha HS, Ahn KM. Osteonecrosis of the jaw after implant surgery in patients treated with bisphosphonates - a presentation of six consecutive cases. *Clin Implant Dent Relat Res.* 2014;16(5):751-61.
26. Wilde F, Heufelder M, Winter K, Hendricks J, Frerich B, Schramm A et al. The role of surgical therapy in the management of intravenous bisphosphonates-related osteonecrosis of the jaw. *Oral Surg Oral Med Oral Pathol Oral Radiol Endod.* 2011;111(2):153-63.
27. Yamano S, Berley JA, Kuo WP, Gallucci GO, Weber HP, Sukotjo C. Effects of nicotine on gene expression and osseointegration in rats. *Clin Oral Implants Res.* 2010;21(12):1353-9.
28. Yoshikazu S, Akira T, Keiji T. Diagnosis and classification of mandibular osteomyelitis. *J Oral Maxillofac Radiol.* 2005; 100(2):207-14.