

Original Research Article

Prevalence of oropharynx cancer caused by HPV compared with genital cancer

Rafaela Guimarães Resende¹
Fernanda Garcia Krinski¹
Allan Fernando Giovanini²

Corresponding author:

Allan Fernando Giovanini
Rua Pedro Viriato Parigot de Souza, n. 5.300 – Campo Comprido
CEP 81280-330 – Curitiba – PR – Brazil
E-mail: afgiovanini@gmail.com

¹ Graduation in Dentistry, Positivo University – Curitiba – PR – Brazil.

² Department of Dentistry, Positivo University – Curitiba – PR – Brazil.

Received for publication: November 1, 2017. Accepted for publication: December 5, 2017.

Keywords:

HPV; oral cancer;
cervical cancer.

Abstract

Introduction: For a long time, the literature has established that HPV may be associated to pharynx cancer. **Objective:** To verify the number of publications in three different databases on the prevalence of oral, esophageal, penile, and cervical-vaginal cancer associated with HPV. **Material and methods:** The publications were verified in Pubmed, Lilacs, and Bireme databases; the keywords “mouth cancer”, “esophageal cancer”, “penile cancer”, and “cervical vaginal cancer” were associated with HPV. Data were tabulated in absolute numbers. **Results:** In all databases, the number of cervical carcinoma was much larger than that of other cancers. **Conclusion:** The number of cervical cancer was the most found associated with HPV because of the histological and specific functional conditions of this site.

Introduction

Human Papillomavirus (HPV), a virus of the family Papillomaviridae [6] installs in skin and mucosae and is significantly able to modify the histophysiology of these sites. Studies show that already more than 200 subtypes of HPV had been identified, which currently are divided on the basis

of the probable oncogenic potential that can be induced by them, that is, they are classified into high and low degrees [15].

The subtypes of HPV considered of high oncogenic risk are those associated to the development of the alterations and type 2 and 3 cervical in intraepithelial neoplasia (CINs) and to

the rapid-invasion neoplasia. Amongst the main oncogenic viruses are types 16, 18, 31, 33, and those with lesser neoplastic capacity are types 35, 39, 45, 51, 52, 56, 58, 59, 68, 73, and 82 [8, 15].

The productive cycle of life of HPVs is related to epithelial cellular differentiation [6]. It is believed that the infection of papillomavirus occurs through microtraumas in the epithelium, exposing the basal cells, which have intense capacity of phagocytosis to the entrance of virus [15]. In the keratinocytes of the basal layer, the genome of the HPV establishes as episome, replicating with the DNA of the cell host and promotes increase of inoculation and viral load, spreading itself, thus, for all surrounding tissues [5].

During the cellular division, the basal cells leave the basal layer, migrating towards the suprabasal region [11], becoming with aspect of a cell with viral inclusion, so-called of coilocytic.

The transmission of the HPV occurs by direct contact with the infected tissue. The HPV is highly contagious, being possible to contaminate with only one exposition. The main forms of contamination are horizontal infection, by sexual contact (genital-genital, oral-genital, or manual-genital), or vertical infection (mother-unborn child), which even so rare, it can compromise the development of child [2].

It must be stood out that the transmissible potential of the illness and its probable translocation

to other anatomical sites justifies the objective of this study, which aimed to promote a refined meta-analysis to compare the current prevalence of the cervical carcinomas with other anatomical sites, including the oropharynx.

Material and methods

The objective of this study was to perform a literature search to analyze the prevalence of the following terms: cervical carcinoma, oral carcinoma, carcinoma of the penis, skin carcinoma related to HPV, including case reports.

For this purpose, the following keywords were used: cancer of the cervix + HPV, oral carcinoma + HPV, penis carcinoma + HPV, skin carcinoma + HPV, case report. The study was accomplished with the literature published in the Pubmed database, which enclose world-wide recognized studies, Lilacs and Bireme covering the Latin America.

Results

The results found in literature are evidenced in the graphs below. Each one of them displays the absolute numbers.

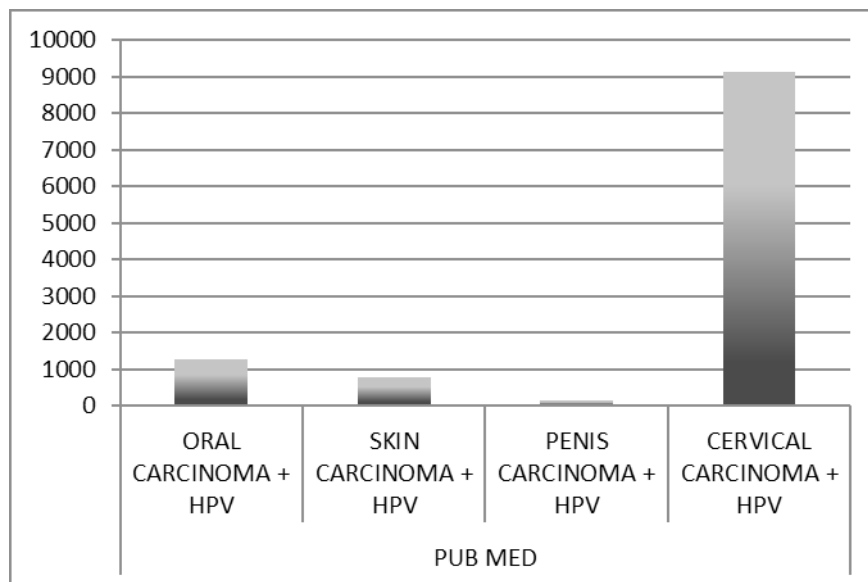


Figure 1 - Articles searched in the Pubmed database with the keywords: HPV, oral carcinoma, skin carcinoma, penis carcinoma, cervical carcinoma

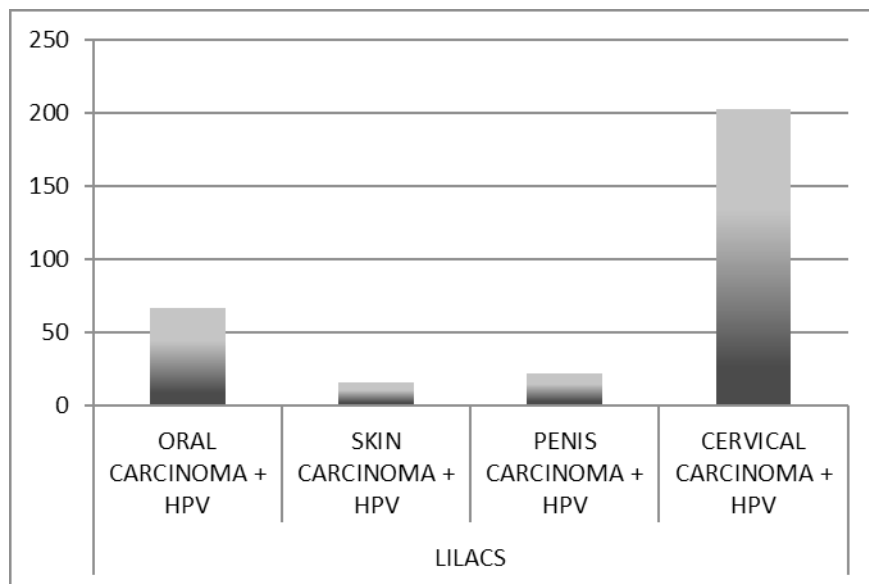


Figure 2 - Articles searched in the Lilacs database with the keywords: HPV, oral carcinoma, skin carcinoma, penis carcinoma, cervical carcinoma

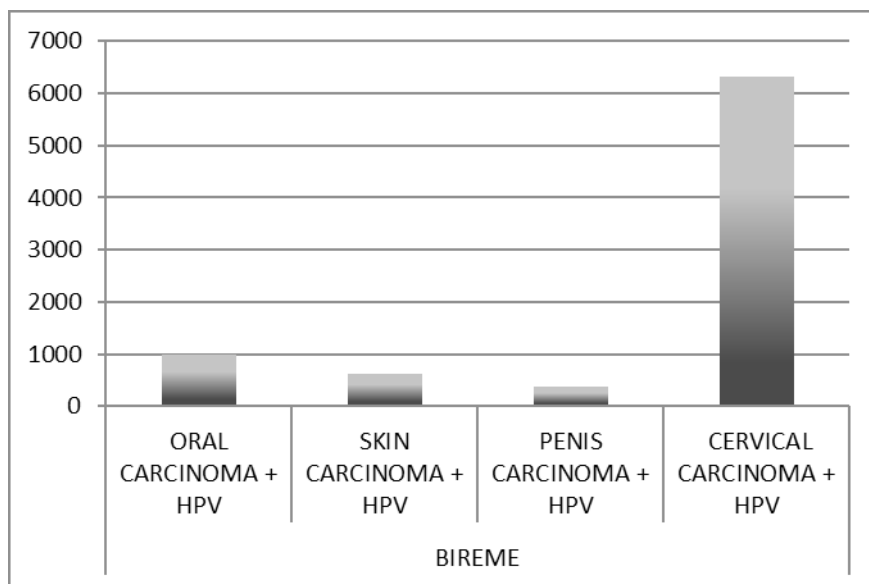


Figure 3 - Articles searched in Bireme database with the keywords: HPV, oral carcinoma, skin carcinoma, penis carcinoma, cervical carcinoma

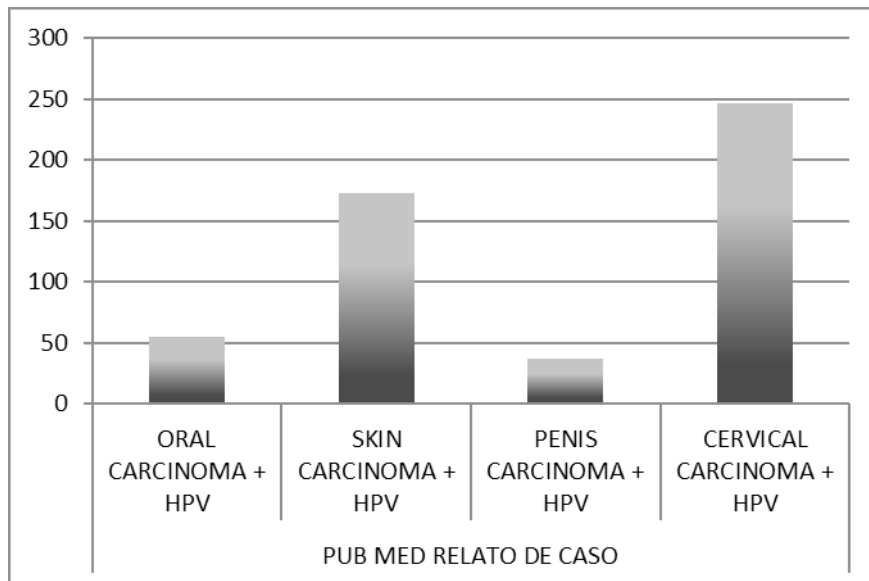


Figure 4 - Articles searched in the Pubmed database with the keywords: HPV, oral carcinoma, skin carcinoma, penis carcinoma, cervical carcinoma, case report

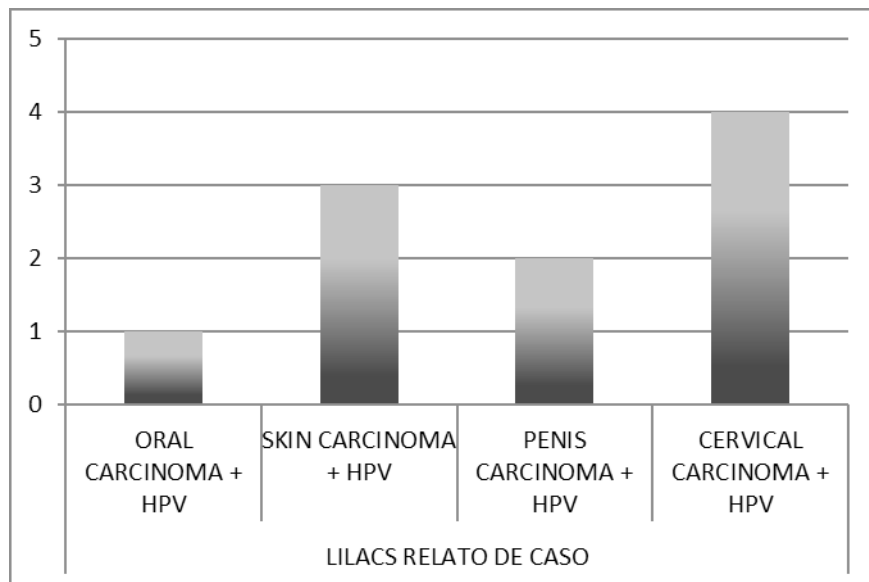


Figure 5 - Articles searched in the Lilacs database with the keywords: HPV, oral carcinoma, skin carcinoma, penis carcinoma, cervical carcinoma, case report

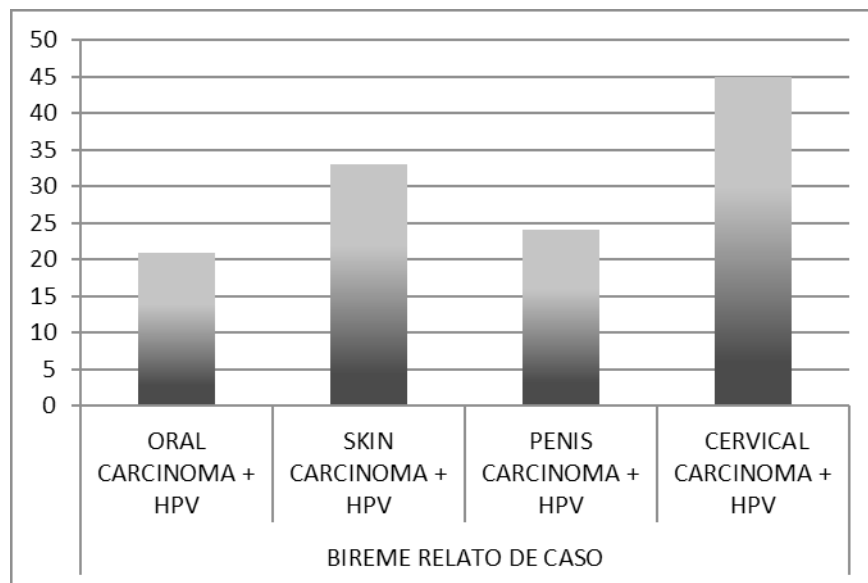


Figure 6 - Articles searched in Bireme database with the word-key: HPV, oral carcinoma, skin carcinoma, penis carcinoma, cervical carcinoma, case report

Discussion

The cancer of oropharynx is considered a great problem in the public health, because of its high incidence and prevalence. Amongst all the oral cancers, 95% are epidermoid carcinoma or squamous cells carcinoma of the lip, mucosa, lateral and upper surface of the tongue, hard/soft palate, and mouth floor. Although this type of cancer has its genesis commonly associated to the conditions of smoking and alcoholism, more frequently oral cancer is associated with HPV [4].

Considering this association, this study performed a systematic evaluation of literature to verify the probable prevalence in relation to HPV and oropharynx cancer and compared the obtained numbers of the relation the HPV/genital cancer.

As expected, the number of cases of cancer in the female genital tract was higher than that of other anatomical sites, in special oropharynx [12]. The physiological and histological nature of these sites can explain the numbers.

When exclusively oral sites and of pharynx/esophagus sites are compared, it is noteworthy the probable super estimation of the cases of cancer with HPV +, which involves more upper airway/digestive tract that possess non-keratinized epithelial morphology. Zhang *et al.* [16] recapitulated the morphology of the HPV in the keratinized epithelium as in the tonsils or oropharynx. The dysplastic cells in these sites had oval to fusiform nuclear

morphology, many times hyperchromatic, scarce cytoplasm, and indistinct edges of cell with little or no squamous maturation. However, biopsies of patients do not show oropharynx cancer with frank invasion; while dysplasia in soft epithelium (without keratinization) with conjunctive invasion [10]. On the basis of this context, we inferred that the keratinization can be protective fact or natural barrier that minimizes the cellular infection to HPV.

This hypothesis can also be inferred to the cervical region. It is well-known that the compromising the vagina lining is very smaller than that endo/ectocervix transition. A fact that must be taken in account is the vaginal keratinization; however, a factor that is important for the intense number of HPV cancer + is the physiology of the presence of the ectopic/eversion of endocervix [9].

With the bipedalism of the human race, the ovulation cycle represented by the menstruation makes the exteriorization of the endocervix. In this exteriorization, the mucus secretor cylindrical epithelium is exposed in locus, in which the tissue lining is stratified squamous. This exteriorization leads to two great problems that can increase the infection for HPV.

The first condition is the squamous metaplasia that makes the tissue to be exteriorized. Metaplasia is a condition where one tissue differentiates in another specialized tissue. In such a way, an intense activity of the stem cells of the germinative layer is necessary, becoming highly proliferative and at the

same time unstable [14]. This genetic instability, when submitted to the viral penetration, leads to the biggest neoplastic action, since the virus inserts into the cellular DNA, modifying the DNA, characterizing a primordial factor to neoplasia [15, 16].

This fact associates to major phagocytic action of the germinative/basal cells. Basal cells commonly phagocytose melanin for nuclear protection. This phagocytic power is also transmitted for exogenous materials, as virus. If the virus will be oncogenic, it increases the probability of the cellular mutation and transformation in cancer [1, 16].

It is not only the metaplastic epithelium that needs attention. Another important physiological factor is that the epithelium of the cervix has intense receptor to the progesterone. Progesterone is a cyclical hormone that has the effect to promote holes in zones of epithelial occlusion when it has receptor to the hormone in the membrane of epithelial cells. To open these holes, the progesterone links to the epithelium it modifies the intracellular proteinic conformation that culminates in the releasing of the zone of occlusion and desmosomes. This fact occurs firstly for the migration of inflammatory cells and transition from mucus to local protection, but also facilitates external-intern the entrance of the virus, which can reach the area of germinative cells, which will phagocytose the virus entering in a neoplastic cycle, as cited above [15].

These physiological factors do not exist in oral mucosa and soft epitheliums, as oropharynx and penis (specifically in gland). These factors corroborate to a significant minor amount of cancer.

Conclusion

Although lesser and with a protective effect to HPV infection, this site is not inert to the cancer, once the disruption, trauma and other habits can take the epithelial fissures. This fact would facilitate the viral transmission and would take to HPV-dependent neoplasia. Thus, during anamnesis, the dentist must be aware of the life habits of patient and to the injury alterations, such as white, warty plates, that occur in oral mucosa.

References

1. Bahrami Shehni M, Kargar M, Mahmoodi P, Motamedi H, Seyfi Abad Shapouri MR. Molecular detection and typing of human papillomaviruses in paraffin-embedded cervical cancer and pre-cancer tissue specimens. *Iran J Cancer Prev.* 2016;9(1):e3752.
2. Baptista Neto C. Papiloma vírus humano (HPV): considerações gerais e bucais. *Full Dent Sci.* 2011;2(8):125-38.
3. Budach V, Johrens K, Kanschak R, Niehr F, Weichert W, Tinhofer L et al. Targeted next-generation sequencing of locally advanced squamous cell carcinomas of the head and neck reveals druggable targets for improving adjuvant chemoradiation. *Eur J Cancer.* 2016;57:78-86.
4. Bussoloti Filho I, Castro TPPG. Prevalência do papilomavírus humano (HPV) na cavidade oral e na orofaringe. *Rev Bras Otorrinolaringol.* 2006;72(2):272-82.
5. Camara GNNL, Cruz MR, Veras VS, Martins CRF. O papilomavírus humano – HPV: histórico, morfologia e ciclo biológico. *Universitas Ciências da Saúde.* 2003;1(1):149-58.
6. Da Cruz AD, Falhari JPB, Souto R. O papilomavírus humano: um fator relacionado com a formação de neoplasias. *Rev Bras Cancerol.* 2005;51(2):155-60.
7. Dediool E, Sabol I, Grce M, Muller D, Manojlovic S. HPV prevalence and p16INKa overexpression in non-smoking non-drinking oral cavity cancer patients. *Oral Dis.* 2016;22(6):517-22.
8. Fujii S, Konishi I, Iwai T, Mori T, Nanbu Y, Nonogaki H. Immunohistochemical analysis of estrogen receptors, progesterone receptors, Ki-67 antigen, and human papillomavirus DNA in normal and neoplastic epithelium of the uterine cervix. *Cancer.* 1991;68(6):1340-50.
9. Lancellotti CLP, Bussoloti Filho I, Xavier SD. Prevalência de achados sugestivos de papilomavírus humano (HPV) em biópsias de carcinoma espinocelular de cavidade oral e orofaringe: estudo preliminar. *Rev Bras Otorrinolaringol.* 2005;71(4).
10. Lewis Jr JS, Zhang L, Gandhi M, Chernock RD, El-Mofty SK. Nonkeratinizing squamous cell carcinoma in situ of the upper aerodigestive tract: an HPV-related entity. *Head and Neck Pathol.* 2017;11(2):152-61.
11. Oliveira MC, Soares RC, Pinto LP, Costa ALL. HPV e carcinogênese oral: revisão bibliográfica. *Rev Bras Otorrinolaringol.* 2003;69(4):553-9.
12. Pernambuco AP, Queiroga RC. Câncer de esôfago: epidemiologia, diagnóstico e tratamento. *Rev Bras Cancerol.* 2006;52(2):173-8.

13. Pires ARC, Castro-Silva II, Silva Júnior J, Coutinho LACR, Bastos OMP. Percepção de vulnerabilidade ao HPV e câncer de cabeça e pescoço: comportamentos sexuais e de risco em jovens de Niterói, RJ. DST – J Bras Doenças Sex Transm. 2012;24(2):85-92.

14. Rapoport A, Silva AF, Fava AS, Oliveira CAB, Tinoco JA, de Souza RP. Correlação da infecção viral pelo papilomavírus humano com as lesões papilomatosas e o carcinoma epidermóide na boca e orofaringe. Rev Assoc Med Bras. 2004;50(3): 252-6.

15. Santos ABR, Ferraz AC, Discacciati MG. Ciclo celular, HPV e evolução da neoplasia intraepitelial cervical: seleção de marcadores biológicos. J Health Sci Inst. 2012;30(2):107-11.

16. Zhang Z, Brown JC, O'Malley Jr BW, Troxel AB, Bauml JM, Rubnitz KR et al. Post-treatment weight change in oral cavity and oropharyngeal squamous cell carcinoma. Support Care Cancer. 2016;24(5):2333-40.