

Case Report Article

Reconstruction of atrophic maxilla with the use of allogenic bone graft and platelet concentrate – clinical case report

Julio Cesar Maurer dos Santos¹
Gabriela da Conceição Cruz Tórtora²
Carla Frehner Andrade^{1, 2}
Rafaela Scariot^{1, 2}
João César Zielak^{1, 2}
Tatiana Miranda Delberador^{1, 2}

Corresponding author:

João César Zielak
Rua Prof. Pedro Viriato Parigot de Souza, n. 5.300 – Campo Comprido
CEP 81280-330 – Curitiba – PR – Brasil
E-mail: jzielak@up.edu.br

¹ Specialization in Implantodontics, Course of Dentistry, Positivo University – Curitiba – PR – Brazil.

² Program of Master and Doctorate Course in Dental Clinics, Positivo University – Curitiba – PR – Brazil.

Received for publication: October 30, 2017. Accepted for publication: December 19, 2017.

Keywords:

bone graft; platelet aggregate; atrophic maxilla; allogenic bone.

Abstract

Introduction: The use of allogenic bone has the advantage of not producing donor area in the patient, which can decrease the morbidity. However, there is an important vascularization demand for this type of graft, which can be increased with the use of platelet concentrate. **Objective:** To report a case of atrophic maxilla reconstruction with particle allogenic bone associated with Platelet Rich Fibrin (PRF). **Case report:** A female patient, who presented a maxilla with a reduced alveolar ridge and pneumatization of the maxillary sinuses, underwent surgery to lift the maxillary sinuses and reconstruct the alveolar ridge, with macro and micro particulate allogenic bone associated with fluid/injectable PRF (i-PRF), and total covering of the graft with PRF membranes, for better accommodation and graft protection. The graft was osseointegrated and able to receive the implants. **Conclusion:** The technique was effective, presenting several advantages in relation to reconstruction with autologous bone, such as shorter surgical time, amount of material for the graft, and less surgical trauma.

Introduction

Edentulous patients have increasingly searched for oral rehabilitation with implant-supported prostheses. However, in many cases, the rehabilitation becomes challenging because of an exacerbated bone deficiency, decurrent of pneumatization of maxillary sinus and vertical and horizontal bone resorption of the alveolar process, needing to bone reconstruction previously to the installation of the implants. Among many of the described techniques of bone grafting for the reconstructions of most extensive atrophic maxilla, autologous graft has greater affinity with the receptors site [5]. However, autologous graft presents as disadvantages: two surgical times, necessity of great donor area, morbidity, postoperative complications, among others. To decrease the risk of complications as the surgical morbidity and time, the use of the allogeneous (or homologous) bone for grafting is presented as an excellent choice, providing the necessary amount of bone and greater comfort to patients [4, 6]. Biologically, such grafting presents less osteoconduction, osteogenesis, and osteoinduction than autogenous bone. Thus, the platelet aggregate

use has grown, among them Platelet Rich Fibrin (PRF), which hydrates the graft with material of the host, improving its biological properties, especially for the angiogenic stimulation, providing a better acceptance of the graft by the organism [14]. This study aimed to report the reconstruction of atrophic maxilla by means of particulate allogeneous graft associated with PRF.

Case report

A female patient aged 52 years, searched the clinic of Implantodontics of the Positive University for implant-prosthetic rehabilitation. She had lost the maxillary teeth many years ago. The patient complained about maladaptation of total denture and revealed the desire to replace them by fixed denture.

At clinical examination, the maxilla was edentulous with extensive alveolar bone loss. The tomographic examination revealed great bilateral pneumatization of the maxillary sinus and significant vertical and horizontal bone loss of the jaw (figure 1).

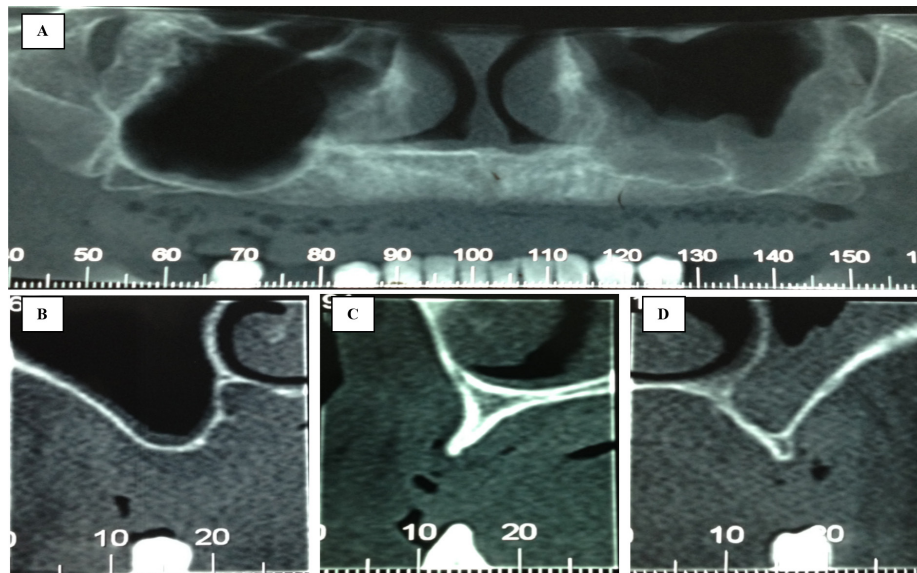


Figure 1 - A) Panoramic view of the initial tomography scan. B) Pneumatization of the maxillary sinus of the right side. C) Horizontal and vertical resorption in anterior maxilla. D) Pneumatization of the maxillary sinus of the left side

The suggested treatment plan was the bilateral lifting of the maxillary sinus and bone grafting in all maxillary alveolar process, for posterior installation of eight implants and construction of maxillary protocol prosthesis. Due to the necessity of extensive bone reconstruction, we opted by particulate allogenic bone graft to prevent an extensive autogenous donor area. To promote greater graft effectiveness, platelet aggregate was indicated to stimulate greater vascularization of the particulate bone and protection in the healing stimulation of the epithelium on the graft, PRF membranes were used over the graft.

The surgical act was initiated with extrabuccal asepsis with PVPI and intrabuccal asepsis with 0.12% chlorhexidine digluconate. After use of topical anesthesia, the infiltration of local anesthesia (Articaine 4% with 1:100.000 adrenalin) was performed.

The surgical access was carried through relaxing incisions, in the posterior region on both sides, and an incision on all the alveolar crest. After the complete detachment of the flap, with the aid of a blade, transversal cuts were performed on the periosteum on the base of all flap, aiming at better elasticity to accommodate the bone graft to be placed. After the total exposition of the surgical site, a Maxicut drill was used to remove all bone spicules and a fine layer of the bone cortical, exposing the bone marrow and allowing a bigger possibility of graft vascularization, primordial factor for its success [8]. Next, the maxillary sinus was exposed.

The access was carried through diamond spherical drill number #6, aiming at creating an oval bone window that decrease the formation of bone spicules that can perforate the sinus membrane. The bone window was carried with 2 mm above the base of the maxillary sinus floor and 1 mm of the lateral wall of the sinus (canine pillar). The osteotomy was initiated superficially, delimiting the bone window of the lateral maxillary sinus wall, being gone deep slowly until remaining a fine layer on the sinus membrane, reaching a more gray or purple coloration of the region, demonstrating proximity with the membrane, because of its vascularization.

After the disclosure of the sinus membrane, the delimitation of a "bone island" assisted in the lift of

the membrane. Following, the raising of the sinus membrane with the aid of curettes (size #1, #2, #3, #4, #5, and #6, Quinelato, Rio Claro, Brazil). The membrane dissection initiated in the base of the maxillary sinus, gently, supporting the bone base of the region, sliding for all maxillary sinus floor. After that, the same gentle movements were carried through the palatal and posterior sinus wall, releasing the sinus membrane was set free in these places, allowing its superior displacement. The limit of the displacement was defined by the planning of the future implant installation, keeping the enough space.

The requested bone for grafting was obtained in the bone bank of the National Institute of Traumatology and Orthopedics (INTO). Three cortical fragments of humerus were used (4 x 2 x 2 cm). Such fragments were triturated with aid of a hand bone grinder (Kopp, Curitiba, Brazil), minutes before the surgery, producing macro and microparticles: about 1 to 2 mm of diameter for macroparticles, and less than 1 mm of diameter for the microparticles. While the bone was triturated, the blood of the patient was removed and ten bottles of PRF and two bottles of liquid fibrin were prepared. This was mixed to the triturated bone, just after the centrifugation, with the objective to help in the hydration and agglutination of particles.

After the bilateral raising of the sinus membranes, providing space for the bone graft, a PRF membrane was delicately seated under the raised sinus membrane, to help in the protection of the membrane at the moment of the bone placement in the region (figure 2A). The particulate bone was deposited on the region in small portions, without much pressure, to supply a good room and to facilitate the graft vascularization. After proper adaptation of the graft, another PRF membrane was adapted in the lateral wall of the maxillary sinus, closing the open bone window, and protecting the maxillary sinus and bone graft.

After the bilateral sinus grafting, the remaining particulate bone was located in all alveolar process of the maxilla, gradually and uniformly, filling all the bone defects (figure 2B).

New PRF membranes were adapted in all extension of the maxilla: about two membranes by hemiarch, allowing a good covering of all graft (figures 2C and 2D).

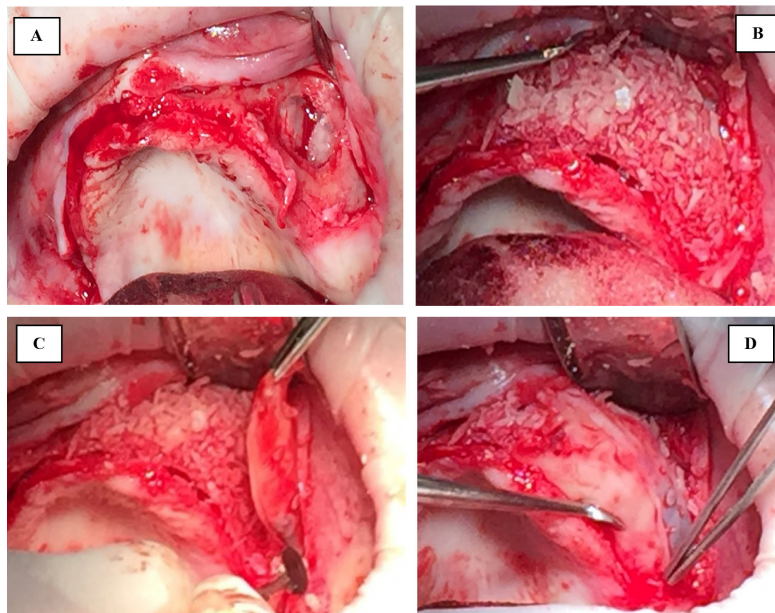


Figure 2 - A) Bone window of the lateral wall of the maxillary sinus. B) Accommodated particulate homologous bone in floor and all hemiarch. C) Accommodated PRF membrane on the particulate bone. D) PRF membrane covering all graft

For flap closing, a continuous suture with nylon thread 5.0 was carried through, with reinforcements in diverse points. The patient was medicated with Amoxicillin 875 mg for 7 days, at every 12 hours; Nimesulide 100 mg, at every 12 hours; and Toragesic 10 mg, at every 12 hours. For hygienic of the mouth, 0.12% Chlorhexidine mouthwash was prescribed, 3 times per day.

As postoperative recommendations, the patient was instructed to use frozen compresses for 48

hours over the region, to rest for 5 days, not to hold sneezes, to prevent suction, to take cold liquid or paste food at the first two days, not to use any prosthesis type for 30 days.

A tomographic examination was taken six months after the surgery, demonstrating a probable osseointegration of the graft, with enough thickness for posterior installation of the dental implants (figure 3).

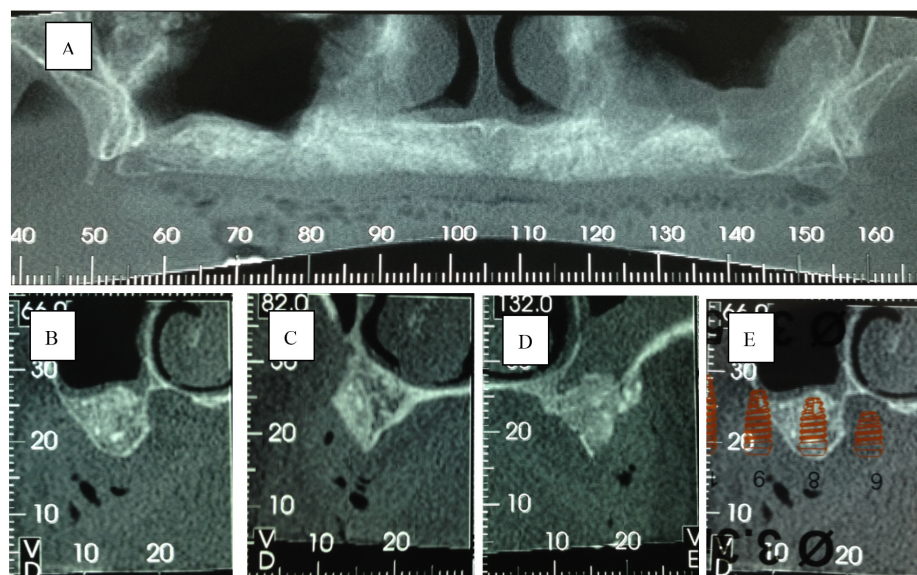


Figure 3 - A) Panoramic view of the tomographic after 6 months of the graft. B) Adaptation of graft in the maxillary sinus, right side. C) Bone thickness in the anterior region of the maxilla. D) Adaptation of graft in the maxillary sinus of the left side. E) Overlapping of the implant ruler on the tomographic cut

Discussion

The edentulous maxilla can present a severe bone resorption, because of the horizontal and vertical bone losses and of the pneumatization of the maxillary sinus [3]. This is aggravated as time went by after the teeth to be lost: the greater the time the teeth had been extracted, the greater the bone resorption; in addition to the use of total denture. Such combination, many times, prevents the adequate implant installation, for the lack of either bone height or thickness.

It is known that the autogenous graft has the best results of bone neoformation for dental implants, because of the best characteristics of osteoconduction, osteogenesis, and osteoinduction [5]. When associated to a good surgical technique and a good donor area, currently, the autogenous graft is "standard gold", presenting a good revascularization, immunological compatibility, and osteogenic potential. The ideal graft material must have the following requirements: 1) limitless supply without compromising the donor area; 2) to promote osteogenesis; 3) to not have immunologic response of the host; 4) to revascularize quickly; 5) to stimulate the osteoinduction; 6) to promote the osteoconduction; 7) to be completely replaced by bone in similar quality and amount similar to that of the host [2]. But it is important to point out that nor always the patient will be willing to undergo two surgical moments, and the postoperative pain and the discomfort are reasons to discourage. Moreover, the patients are each time more clarified and demanding, waiting satisfactory results with the possible less invasive surgeries.

Accordingly, the use of allogeneous, xenogeneous, and alloplastic materials has grown. Of these, allogeneous bone seems to demonstrate better adaptation when well stored and manipulated [7, 13].

Per many years the bone in block has been used for grafting, searching for an adequate increase of thickness of the alveolar ridge for a posterior three-dimensional installation of dental implant [12]. However, for the success of in block graft, it has necessity of total adaptation to the receiving bone wall, making possible a greater contact of the surfaces and, consequently, osseointegration. Thus, the technique is of difficult handling, a time that each organism has proper anatomy, demanding extreme ability of the surgeon. Aiming at better adaptation of bone graft and the receiving site, to break up the bone for its posterior adaptation, it has been an excellent treatment option, a time that can generate bone thickness necessary to make possible the best graft vascularization, promoting osseointegration [9].

In recent years, with the advent of platelet aggregates, the bone and tissue healing gained a new and important reinforcement [10]. The platelet rich fibrin (PRF) came from a process of distinguishing centrifugation, which separates platelet aggregates, in special the fibrin, capable to assist the soft and hard tissues. PRF comes from the organism, is non-toxic, without immune reaction and rich in growth factors, an important ally in the tissue repair. The PRF has potential to reduce the discomfort and possible postoperative adverse effect, as infections, insufficient closing of the wound, and delay in bone neoformation [14].

With passing of the years, simpler and cheap protocols have been developed for the platelet aggregate in the dental offices, easing and spreading its use. Basically, the process for production of the fibrin matrix consists of the centrifugation of the blood not coagulated of the patient who, for the process of separation for density gradient, is separated into red globules and leukocytes, making possible the use of specific components of coagulation [11].

The use of the liquid fibrin, obtained in lesser time by centrifugation, has as purpose to hydrate the bone graft and to assist in its acceptance for the organism. Combined with the particulate bone, it can assist in local revascularization [15].

Conclusion

It is known that the allogeneous bone has greater risks related to the immunogenicity, minor osteogenesis and osteoinduction, greater infection risk and transmission of illnesses when compared with the autogenous bone. However, it presents benefits, as absence of surgical risk in the donor area, high amount of bone and reduction of surgical time, and potentializing in the association with PRF, with very little contraindications. Atrophic maxilla (due to several reasons) that do not allow the adequate installation of dental implants can be reconstructed associating such techniques, depending on a good surgical technique, adequate manipulation of the graft, and postoperative care. With this, the oral rehabilitation of the patient can be successful. In the presented case report, it was evidenced that the particulate allogeneous bone associated with platelet aggregate demonstrated a good adaptation and provided a good bone remodeling, providing enough bone volume for posterior installation of dental implant and construction of implant-supported prosthesis.

References

1. Betoni Júnior W, Esteves JC, Saito LY. Levantamento de seio maxilar com implante imediato em rebordo severamente atrófico – relato de caso. *ImplantNews*. 2009;6(6):673-7.
2. Boyne PJ, James RA. Grafting of the maxillary sinus floor with autogenous marrow and bone. *J Oral Surg*. 1980;38(8):613-6.
2. Cardoso RF, Capella LRC, Di Sora G. Levantamento de seio maxilar. São Paulo: Artes Médicas; 2002. p. 467-81.
3. Coletti FL. Avaliação de enxerto ósseo homólogos corticais em humanos: análise tomográfica, histológica e histomorfométrica. Araraquara; 2013.
4. Dell Valle RA, Carvalho ML, Gonzalez MR. Estudo do comportamento de enxerto ósseo com material obtido dos bancos de tecidos musculoesqueléticos. *Revista de Odontologia da USP*. 2006;18(2):189-94.
5. Garcia RJ, Feofilof ET. Técnicas de obtenção, processamento, armazenamento e utilização de homoenxertos ósseos, protocolo do Banco de Ossos da Escola Paulista de Medicina. *Rev Bras Ortop*. 1996;31(11):895-903.
6. Jardim ECG, Santos PL, Santiago Junior JF, Jardim Júnior EG, Aranega AM, Garcia Júnior IR. Enxerto ósseo em odontologia. *Rev Odontol Araçatuba*. 2009;30(2):24-8.
7. Klassmann FA, Coro ER, Thomé G, Melo ACM, Sartori IAM. Enxertos ósseos autógenos de áreas doadoras intra-bucais e procedimentos clínicos integrados possibilitando reabilitação estética e funcional. *RGO*. 2006;54(4):388-92.
8. Marx RE, Carlson ER, Eichstaedt RM, Schimmele SR, Strauss JE, Georgeff KR. Platelet-rich plasma. Growth factor enhancement for bone grafts. *Oral Surg Oral Med Oral Pathol Oral Radiol Endod*. 1998;85:267-57.
9. Mazor Z, Peleg M, Garg AK, Luboshitz J. Platelet-rich plasma for bone graft enhancement in sinus floor augmentation with simultaneous implant placement: patient series study. *Implant Dent*. 2004;13:65-70.
10. Oliveira Filho MA. Obtenção do plasma rico em plaquetas em coelhos: introdução de um modelo animal experimental [Tese]. Curitiba: Hospital Universitário Evangélico de Curitiba; 2003.
11. Ortega-Lopes R, Nóia CF, Chaves Netto HDM, Cidade CPV, Andrade VC. Otimização em reconstrução total de maxila através da modificação estrutural do enxerto e diminuição do intervalo cirúrgico. *ImplantNews*. 2012;9(3):383-92.
12. Petrunaro PS, Amar S. Localized ridge augmentation with allogenic block grafts prior to implant placement: case reports and histologic evaluations. *Implant Dentistry*. 2005;14(2):139-48.
13. Petrunaro PS. Using platelet-rich plasma to accelerate soft tissue maturation in esthetic periodontal surgery. *Compend Contin Educ Dent*. 2001;22(9):729-32.
14. Whitman DH, Berry RL. A technique for improving the handling of particulate cancellous bone and marrow grafts using platelet gel. *J Oral Maxillofac Surg*. 1998;56:1217-8.