

Case Report Article

Medication-related osteonecrosis of the jaw (MRONJ) treated with piezosurgery – case report and review of literature

Analicy Ticiani Perini¹
Greison Rabelo de Oliveira¹
Fabiana Seguin¹

Corresponding author:

Analicy Ticiani Perini
Rua Universitária, n. 2.069 – Jardim Universitário
CEP 85819-110 – Cascavel – Paraná – Brasil
E-mail: analicy.perini@gmail.com

¹ Department of Dentistry, Universidade Estadual do Oeste do Paraná – Cascavel – PR – Brazil.

Received for publication: March 6, 2018. Accepted for publication: August 28, 2018.

Palavras-chave:

bisphosphonates;
piezosurgery; MRONJ.

Abstract

Introduction and Objective: Medication-related osteonecrosis of the jaw (MRONJ) is a recently described adverse effect associated with anti-resorptive and anti-angiogenic agents. The objective of this article is to report a case of MRONJ treated surgically using a ultrasonic device (piezosurgery). **Case report:** A 66 year-old female being treated with a bisphosphonate (alendronate) for more than 4 years developed MRONJ of the lower jaw after dental extraction. Two debridement attempts of necrotic bone tissue and primary intention closure with conventional techniques were performed, without success. Finally, treatment with antibiotics and piezosurgery led to disease remission. **Conclusion:** Even though more studies are needed to create a protocol that might include this therapeutic modality, specially when there was no success with conservative management or conventional treatment techniques, the use of ultrasonic devices is an option for treatment of MRONJ.

Introduction

The Bisphosphonate-Associated Osteonecrosis of the Jaw (BRONJ) was described at first by Marx in 2003 [5], since then, the number of reports of this complication is growing. Recently, its denomination was changed to Medication-Related Osteonecrosis of the Jaw (MRONJ), due to a higher number of cases

involving other antiresorptive and antiangiogenic medicines, such as denosumab [13].

Bisphosphonates (BP) are inhibitors of osteoclasts, which are cells that have a fundamental action in reducing bone resorption. BPs have in their chemical composition two phosphorus atoms connected to a carbon atom. This structure confers

resistance to enzymatic hydrolysis and allows for fixation of this medicine to hydroxyapatite crystals and connection to the bone surface [6]. Intravenous bisphosphonates (BP IV) are indicated in the management of conditions related to cancer, such as hypercalcemia, metastasis associated to breast, prostate and lung tumors, multiple myeloma and, in some circumstances, osteoporosis. Oral bisphosphonates (oral BP) are used clinically for osteoporosis, osteopenia, Paget's disease and osteogenesis imperfecta [13].

The incidence of MRONJ in studies of the American Association of Oral and Maxillofacial Surgeons (AAOMS) published in 2014 shows that patients with cancer who use zoledronate, a formulation of BP IV, have a risk of 1% of developing MRONJ, which means 50 to 100 times higher than placebo. Patients with osteoporosis and oral BP use for more than 4 years have a risk of MRONJ of 0.1% - 0.21%. Thus, the risk of developing MRONJ in patients exposed to BP for the treatment of osteoporosis is about 100 times lower than that for patients receiving the medication for cancer treatment. The mean time of BP use in patients diagnosed with MRONJ was 4.4 years [13].

The pathophysiology is not totally elucidated yet. Some hypothesis that try to explain the unique localization of the MRONJ in the jaws include altered remodeling and resorption, angiogenesis inhibition, constant microtrauma, suppression of innate or acquired immunity, vitamin D deficiency, soft tissue toxicity, inflammation and infection [13]. In other words, the selective accumulation of BP in the jaws associated with a specially high bone turnover in these bones and the continuous exposition of them to the external environment through dental involvement, due to frequent and recurrent dental infections, which could contiguously affect the maxillaries, leading to local tissue acidosis possibly acting as a trigger for MRONJ [15].

Diagnosis of MRONJ can be made if the following characteristics are present in a patient: 1) current or previous treatment with antiresorptive or antiangiogenic medication; 2) exposed bone or bone that can be probed through an intraoral or extraoral fistula in the maxillofacial region that has persisted for eight weeks or more; 3) no history of radiation exposure or metastatic disease in the jaws [13]. The radiographic aspect can be defined as: diffuse bone sclerosis, presence of sequestration, periosteal reaction and oro-antral fistula, such as diffuse radiolucent areas [11]. The median age of patients that develop MRONJ is 70 years old (38 to 88 years old) [7].

Treatment is based on disease staging and varies from conservative hygiene measures, symptomatics, antibiotics and surgery. When a more invasive treatment is indicated, the manipulation of bone tissue is pursued in a more conservative fashion, with the realization of minimally traumatic osteotomies. In this context, the debridement or resection performed with piezosurgery (ultrasonic device) is an option of treatment which presents advantages such as its antibacterial effect [1], less trauma, less bleeding (trans and postoperative) and a selective cut of only bone tissue [10].

This article aims to report a MRONJ case after tooth extraction in a patient using oral BP, treated with piezosurgery.

Case report

Patient AGS, 66 year-old female, had as chief complaint that she didn't achieve adequate healing after dental extraction. It was observed that her dental alveolus did not heal 1 year after the extraction of tooth 37 (mandibular left second molar). In her past medical history, she was found to have depression, systemic arterial hypertension, hypothyroidism, osteoporosis and rheumatoid arthritis for which she was making use of anti-hypertensives, diuretics, antidepressants, anti-acids and treatment for hypothyroidism. She had already been submitted to a dental abscess drainage in the same region of the tooth extraction and two debridement attempts of the extraction site with closing by first intention. However, those interventions were unsuccessful and progressed to the loss of another elements: 36 (mandibular left first molar), 33 (mandibular left canine), 32 (mandibular left lateral incisor), 31 (mandibular left central incisor) and 41 (mandibular right central incisor). Since, at first, her condition was considered to be osteomyelitis, she had undergone antibiotic therapy with intravenous ceftriaxone 1 gram per day, substituted for clindamycin 600mg three times a day, and finally, ciprofloxacin 1 gram twice a day to be administrated orally, coming to a total of 30 days of antibiotic therapy. After the failure of the above treatment, our Oral and maxillofacial surgery team was consulted and it was noticed that she made use of alendronic acid and prednisone for over four years for treatment of osteoporosis and rheumatoid arthritis under a rheumatologist's supervision. During inspection of the oral cavity, there was an area of necrotic bone tissue exposed in the body of the left mandible on the alveolar crest,

an active vestibular fistula in the region of the 33 (mandibular left canine) with purulent drainage to manipulation (figure 1). Because the patient did not have a radiotherapy or metastatic disease history, the diagnosis of osteonecrosis of the jaw (MRONJ) was concluded, due to alendronate use. In the image obtained by a panoramic radiography, it could be noticed the alveolus of the 37 (mandibular left second molar) tooth and an alteration of bone density in the anterior region of the jaw (figure 2). From the diagnosis confirmation and contact with the rheumatologist, alendronate was suspended. The plan of treatment involved a surgical procedure under general anesthesia for the performance of an alveoloplasty, aiming for the removal of necrotic bone and closure of the wound by primary intention, with extraction of the last present teeth on the right mandibular region. The osteotomies were performed totally with piezosurgery (figure 3). The wound closure was performed in two layers. First, deeper tissue suture with a polyglactin 910 thread, with simple stitches interrupted in “U”, which promoted the eversion of the wound borders, followed by a superficial layer of suture with interrupted simple stitches, in order to grasp the margins of the wound better (figure 4). The patient was discharged from the hospital in the following morning, with prescribed antibiotic therapy for 30 days (amoxicillin 500mg 1 capsule every 8 hours), besides analgesic and anti-inflammatory medications. Surgical wound care involved oral hygiene with careful brushing of the superior dental arch and tongue, associated to the use of chlorhexidine 0.12%, twice a day since the third postoperative day. Postoperative consults happened after day 7, 14, 21 and 30, and, after that period, postoperative control was monthly. During this period, in which the patient remained with occluded wounds, it was observed an absence of fistulae and signs or symptoms of infection. In a panoramic radiograph of 16 months postoperatively, the bone aspect was consistent with normality with the mandible totally edentulous and the alveolar ridge regularized, preventing, then, trauma by the use of total prosthesis (figures 5 and 6). After 24 months, new regions of bone exposure or fistulae presence were not observed.

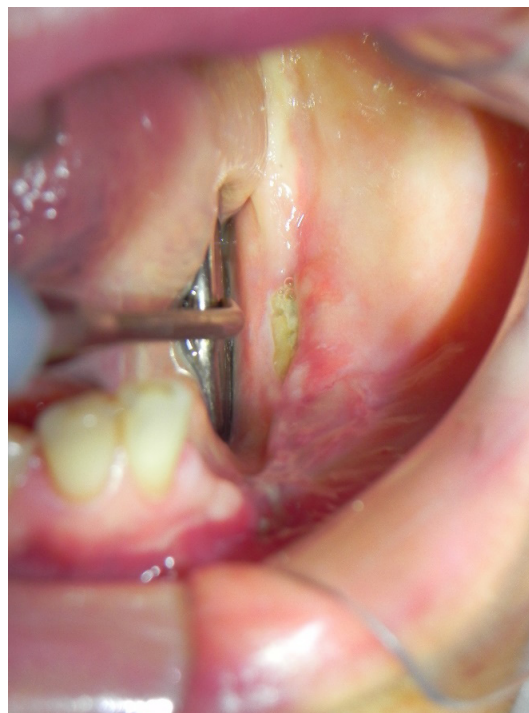


Figure 1 – Initial aspect, we observed a necrotic bone exposure in the region of tooth 37 (mandibular left second molar)

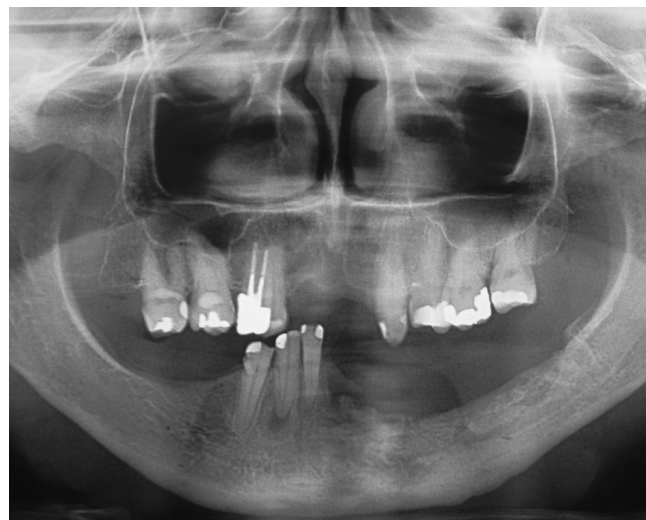

Figure 2 – Initial radiographic image, with bone exposure and bone density alterations in the right anterior mandibular region

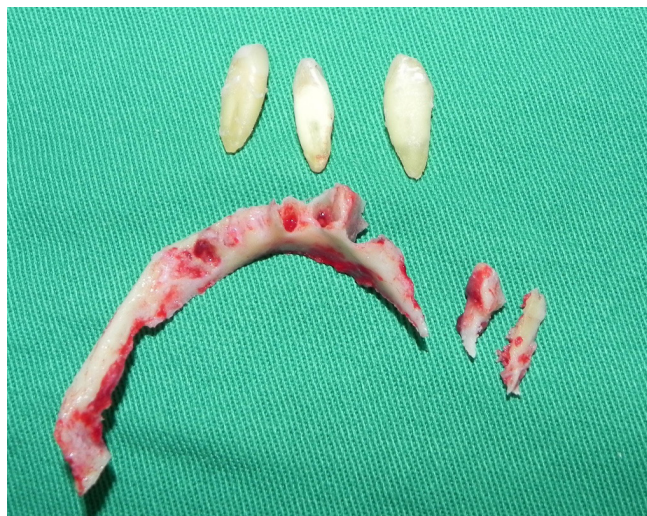

Figure 3 - Bone fragment corresponding to the residual alveolar process involved and the teeth extracted

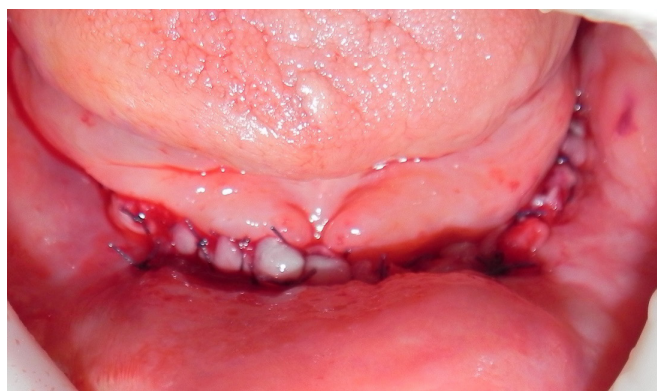

Figure 4 - Immediate postoperative. Closure of the borders was performed by primary intention and with no excessive tension

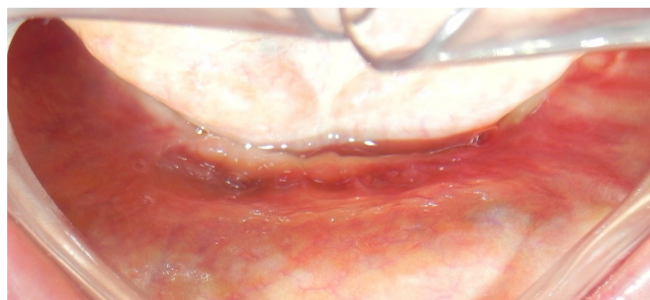


Figure 5 - 16 month postoperative follow-up, with an aspect that shows appropriate tissue repair

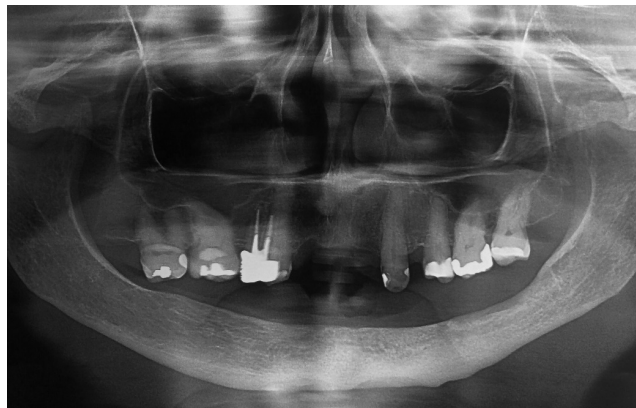

Figure 6 - Panoramic radiography at 16 months postoperative

Discussion

In the current article, it was presented a MRONJ case in a 66 year-old female, after having performed a dental extraction and using oral BP for osteoporosis probably related to rheumatoid arthritis and its treatment (corticosteroids). The epidemiology of our case was consistent with a very relevant study found in the literature. Franco *et al.* [3] with 203 patients diagnosed with MRONJ, showed that approximately 75% of patients were female, with a mean age of 67.8 years old. Although, in opposition to our report, 71% of the patients administrated BP for oncologic treatment and 77.34% receiving the medicine by parenteral administration. As of our MRONJ case, predilection for the jaw compared to the maxilla (1.8:1) was observed, and the dental extraction was the most common associated factor.

Another important factor to be considered, is that the patient of the report has rheumatoid arthritis and was using daily corticoids for more than 5 years. According to the literature, corticoids administred in high doses interact with cell groups involved in the bone turnover process, such as osteoclasts, osteoblasts and osteocytes, stimulating the resorption process and inhibiting bone formation. As a result of these alterations, in each cycle of bone remodeling, around 30% less of bone tissue is produced in comparison to the normal conditions [14]. We believe that the use of a corticosteroid contribute to MRONJ development.

Risk factors such as duration of use of bisphosphonates, use of steroids, advanced age,

diabetes, suppressed markers of bone turnover, genetic factors, local factors, oral surgeries, anatomic location and concomitant oral diseases are also mentioned in the consensus of the Korean Association of Oral and Maxillofacial Surgeon [7].

The staging and proposed treatment for each stage of MRONJ are summarized in the table I [13].

Table I – MRONJ staging and treatment

Stage	Diagnosis	Treatment
Patients at risk	Asymptomatic and with no apparent necrotic bone, but who received oral BP or IV treatment.	No treatment, but patients must be informed about the symptoms and risk of developing MRONJ.
Stage 0	Patients who do not present necrotic bone, but present non-specific symptoms, clinical or radiographic findings*.	Symptomatic treatment. Analgesics and antibiotics when necessary. These patients must be monitored closely.
Stage 1	Exposed and necrotic bone or fistula which probes to bone in asymptomatic patients and no evidence of infection. They can present with radiographic findings mentioned in stage 0.	No treatment is needed, only informing patients and reviewing the indication of BPs. Consider using oral topical chlorhexidine 0.12%.
Stage 2	Exposed and necrotic bone or fistula which probes to the bone with evidence of infection. Usually symptomatic patients. They can also present with the radiographic findings mentioned in stage 0.	Symptomatic treatment with antibiotics, analgesics and rinses. Debridement** to alleviate the irritation of the soft tissues area and infection control.
Stage 3	Exposed and necrotic bone or fistula which probes to the bone with evidence of infection and one or more of additional characteristics***.	Debridement including resection in conjunction with antibiotic therapy, palliative treatment with resolution of the acute infection and pain.

* Unexplained toothache; acute pain in the body of the mandible which can radiate to the TMJ; sinus pain that can be associated with inflammation and increase in the maxillary sinus wall; alteration of neurosensory function.

Clinical findings: Dental loss not caused by chronic periodontal disease; periapical/periodontal fistula which is not related to caries or pulpal necrosis;

Radiographic findings: alveolar bone loss or resorption not caused by chronic periodontal disease; modification in the trabecular pattern - dense woven bone and persistence of unremodeled bone in extraction areas; regions of osteosclerosis involving the alveolar bone and the enclosing basilar bone; increase of the periodontal ligament thickness (thickening of the lamina dura and decreased size of the periodontal ligament space).

** Independent of disease stage, bone sequestrs should be removed to ease the repair of soft tissue. Teeth extraction when exposed and necrotic bone is present must be considered, because the extraction is unlikely to exacerbate the necrotic process established.

*** Exposed necrotic bone expanding beyond the alveolar bone region; pathologic fracture; extra-oral fistula; oral antral communication; osteolysis extending to the inferior border of the mandible or sinus floor.

As this patient fits in stage 2 of MRONJ (table I), the AAOMS's recommendation includes symptomatic treatment with antibiotics, analgesics, rinses and debridement to relieve the irritation of soft tissue and infection control. In our patient's case, considering the clinical aspects of the lesion, the interdental crest already exposed, anterior extension on the lingual region and necessity of regularization of the ridge for a subsequently adaptation of prosthesis, an alveolectomy was performed.

Before our consultation, two surgical procedures were performed to remove the necrotic bone tissue and close the wound without success. We believe that the failure of these procedures may have happened due to the use of rotating instruments, which promote tissue warming, besides the antibiotic therapy for a short period and alendronate maintenance in the course of the disease.

In the reported case, due to the need to reduce surgical trauma and not having a definite protocol

for the debridement and resection, piezosurgery was chosen. Furthermore, conventional techniques have already been tried in two previous procedures. Thus, the advantages of piezosurgery could be useful.

The piezosurgery is used in a variety of oral surgical procedures and has therapeutic advantages that include: more accurate, selective and safe cut (specially for causing less damage to the osteocytes), a cleaner operative field due to the attached oral irrigation and preservation of important structures like nerves and membranes [2].

The effects of this instrument use in cell viability are essential to bone regeneration [2]. Gulnahr's *et al.* [4] study evaluated a conventional technique versus piezosurgery in third molar extractions impacted through the measurement of heat-shock protein 70 (Hsp 70). This protein signalize the intensity of the stress and injury to the tissue and is induced to keep the homeostasis under stress conditions. In the conventional technique the expression of Hsp 70 was twice that of piezosurgery. Besides that, the piezo cut of the bone tissue is more accurate and promotes less bleeding, and that reduces the stress in the alveolar bone and can help the function of repair cells postoperatively. In addition to this, cell viability, bone deposition and remodeling after osteotomy seems to be better with piezosurgery compared to conventional drills [9]. In the aspects related to the orthognathic surgery using piezosurgery, osteotomies had reduced blood loss and fewer lesions in the inferior alveolar nerve, with no need of extra invested time [8].

Rashad *et al.* [12] showed a limitation of piezosurgery: the preparation of the implant placements take longer and generates higher temperatures in the bone compared to conventional technique. Tsai *et al.* [16] outlined that, in third molars extraction, regarding recovery of the initial wound and bone healing, when compared piezosurgery and conventional techniques, no significant differences between both was found.

In a series of 9 cases of MRONJ treated with piezosurgery, with an one year follow-up, there was complete resolution in all cases after 2 weeks of the procedure, with no signs or symptoms of recurrence. This suggests that piezosurgery combined with antibiotic therapy can lead to the cure of MRONJ. The application of ultrasonic vibrations and powerful cavitation associated with the medical treatment, can reduce the quantity of microorganisms around the affected bone. According to previous reports, low frequency sound waves would be capable of erradicating more than 85% of the bacterias in the biofilm, when applied simultaneously with the use of antibiotics, for 3 species of clinical relevance: *E. coli*, *S. epidermidis* and *Pseudomonas aeruginosa* [1].

More randomized clinical studies of patients undergoing the same treatment modality are necessary for a recommendation based in stronger evidence. But, the positive results encourage future in vivo studies to possibly suggest a surgical treatment protocol of MRONJ which includes piezosurgery.

Conclusion

The management of patients with MRONJ involves the awareness about the clinical staging of the disease according to AAOMS consensus. The piezosurgery choice as a method to minimize surgical trauma was shown an efficient method for MRONJ resolution and disease control in a follow up of 24 months. More studies are necessary to create a protocol that includes this method of treatment.

References

1. Blus C, Szmukler-Moncler S, Giannelli G, Denotti G, Orrù G. Use of ultrasonic bone surgery (piezosurgery) to surgically treat Bisphosphonate-Related Osteonecrosis of the Jaws (BRONJ). A case series report with at least 1 year of follow-up. The Open Dentistry Journal. 2013;7:94-101.
2. Danza M, Guidi R, Carinci F. Comparison between implants inserted into piezo split and unsplit alveolar crests. J Oral Maxillofac Surg. 2009;67:2460-5.
3. Franco S, Miccoli S, Limongelli L, Tempesta A, Favia G, Maiorano E et al. New dimensional staging of Bisphosphonate-Related Osteonecrosis of the Jaw allowing a guided surgical treatment protocol: long-term follow-up of 266 lesions in neoplastic and osteoporotic patients from the University of Bari. Int J Dent. 2014;2014:935657.
4. Gulnahr Y, Huseyin Kosger H, Tutar Y. A comparison of piezosurgery and conventional surgery by heat shock protein 70 expression. Int J Oral Maxillofac Surg. 2013;42:508-10.
5. Hamada H, Matsuo A, Kiozumi T, Satomi T, Chikazu D. A simple evaluation method for early detection of bisphosphonate – related osteonecrosis of the mandible using computed tomography. Journal of Cranio-Maxillo-Facial Surgery. Jan 2014;42:924-9.
6. Jaimes M, Oliveira GR, Olate S, Albergaria Barbosa JR. Bifosfonatos asociado a osteonecrosis de los maxilares. Revisión de la literatura. Avances em Odontoestomatología. 2008;24(3):219-24.

7. Kim KM, Rhee Y, Kwon YD, Kwon TG, Lee JK, Kim DY. Medication Related Osteonecrosis of the Jaw: 2015 position statement of the Korean Society for Bone and Mineral Research and the Korean Association of Oral and Maxillofacial Surgeons. *J Bone Metab.* 2015;22:151-65.
8. Landes CA, Stübinger S, Rieger J, Williger B, Ha TK, Sader R. Critical evaluation of piezoelectric osteotomy in orthognathic surgery: operative technique, blood loss, time requirement, nerve and vessel integrity. *J Oral Maxillofac Surg.* 2008;66:657-74.
9. Mouraret S, Houschyar KS, Hunter DJ, Smith AA, Jew OS, Girod S et al. Cell viability after osteotomy and bone harvesting: comparison of piezoelectric surgery and conventional bur. *Int J Oral Maxillofac Surg.* 2014;43:966-71.
10. Pekovits K, Wildburger A, Payer M, Hutter H, Jakse N, Dohr G. Evaluation of graft cell viability – efficacy of piezoelectric versus manual bone scraper technique. *J Oral Maxillofac Surg.* 2012;70:154-62.
11. Mourão CFAB, Moura AP, Manso JEF. Treatment of bisphosphonate related osteonecrosis of the jaw: literature review. *Rev Bras Cir Cabeça Pescoço.* 2013;42(2):113-7.
12. Rashad A, Kaiser A, Prochnow N, Schmitz I, Hoffmann E, Maurer P. Heat production during different ultrasonic and conventional osteotomy preparations for dental implants. *Clin Oral Implants Res.* 2011;22(12):1361-5.
13. Ruggiero SL, Dodson TB, Fantasia J, Goodday R, Aghaloo T, Mehrotra B et al. American Association of Oral and Maxillofacial Surgeons position paper on medication-related osteonecrosis of the jaw – 2014 update. *J Oral Maxillofac Surg.* 2014;72:1938-56.
14. Sewerynek E, Stuss M. Steroid-induced osteoporosis. *Aging Health.* 2012;8(5):471-7.
15. Spinelli G, Torresetti M, Lazzeri D, Zhang YX, Arcuri F, Agostini T et al. Microsurgical reconstruction after bisphosphonate – related osteonecrosis of the jaw: our experience with fibula free flap. *The Journal of Craniofacial Surgery.* 2014;25(3):788-92.
16. Tsai SJ, Chen YL, Chang HH, Shyu YC, Lin CP. Effect of piezoelectric instruments on healing propensity of alveolar sockets following mandibular third molar extraction. *Journal of Dental Sciences.* 2012;7:296-300.