

Case Report Article

Erupted odontomas: a report of two unusual cases

Santosh Patil¹
Farzan Rahman²
Shoaib R. Tipu³
Sumita Kaswan⁴

Corresponding author:

Santosh Patil
Dept. of Oral Medicine and Radiology – Jodhpur Dental College – Jodhpur National University
Jhanwar Road – Naranadi – Jodhpur (Raj).342001 – India
E-mail: drpsantosh@yahoo.com

¹ Department of Oral Medicine and Radiology, Jodhpur Dental College, Jodhpur National University – Jodhpur (Raj).342001 – India.

² Department of Oral Pathology and Microbiology, Jaipur Dental College and Hospital Jaipur (Raj) – India.

³ Department of Oral and Maxillofacial Surgery, Jaipur Dental College and Hospital Jaipur (Raj) – India.

⁴ Department of Conservative Dentistry and Endodontics, Jodhpur Dental College, Jodhpur National University – Jodhpur (Raj).342001 – India.

Received for publication: June 9, 2011. Accepted for publication: August 2, 2011.

Keywords:

hamartoma; compound odontoma; erupted.

Abstract

Introduction: Odontomas are the most common odontogenic tumors of the jaws which are benign, slow growing and nonaggressive. They are usually asymptomatic and are diagnosed on routine radiological examination. The eruptions of odontomas are uncommon and very few cases are reported in the literature. **Objective:** To report two rare cases of erupted compound odontomas. **Case report:** Two cases of erupted compound odontomas are reported in middle aged patients. Erupted miniature teeth-like structure were seen on clinical examination. The condition was diagnosed on the basis of conventional intraoral radiographs and histopathological examination. Both cases were treated by surgical excision under local anaesthesia without any complications. **Conclusion:** Odontomas are benign tumors with uncertain etiology. Odontomas erupting in the oral cavity is an infrequent situation. Surgical excision is the treatment of choice in all such cases followed by histopathological examination to confirm the clinical diagnosis.

Introduction

Odontomas are considered as hamartomas of aborted tooth formation rather than true neoplasm. The term odontoma was first coined by Broca in 1866, who defined it as a tumor formed by overgrowth of complete dental tissue [2]. They are composed of enamel, dentin, cementum and occasionally pulp tissue [10]. The exact aetiology of odontomas is uncertain, different factors such as local trauma, infection, growth pressure, hereditary and developmental influences may be implicated [2]. According to 2005 WHO classification of odontogenic tumours, there are two types of odontomas, compound and complex odontomas [1]. Odontomas have also been classified as central odontoma (which occur inside the bone), peripheral odontoma (which occur in the soft tissue covering the tooth-bearing portions of the jaws which has the tendency to exfoliate), and erupted odontoma [4]. Although odontomas are common, eruption into the oral cavity are exceptionally rare. Two cases of erupted compound odontomas, having tendency to exfoliate are reported.

Case report one

A twenty-five year old female reported to the Clinics with a complaint of a painless mass in the right side of upper jaw since five months. Patient was apparently healthy with no significant past medical and dental history. Intraoral examination revealed a yellowish white small tooth-like structure on the labial gingiva, mesio-apically to 13 measuring about 0.5×0.5 cm (figure 1). Adjacent mucosa was apparently normal and showed no signs of inflammation, infection, erythema or ulceration. The mass was labially located, non-tender, mobile and hard in consistency. Intraoral periapical radiograph revealed well defined multiple radiopaque structures located between 11, 12 and 13 (figure 2). On the basis of clinical and radiological findings a diagnosis of erupting odontoma was made. The mass was surgically removed under local anesthesia. On surgical exploration, two miniature teeth-like structured were removed along with the erupted one (figure 3). All three specimens were sent for histopathological examination. Tooth-like structure made up of enamel, dentin and cementum were reported in ground section confirming the diagnosis of compound odontoma (figure 4).

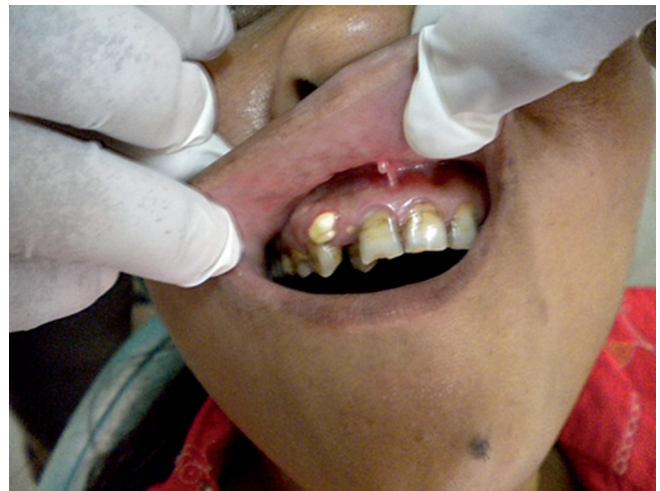

Figure 1 - Clinical photograph showing erupted odontoma

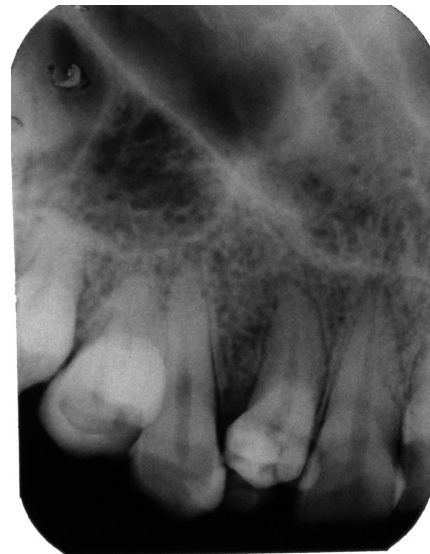

Figure 2 - IOPA radiograph showing radiopaque tooth-like structures

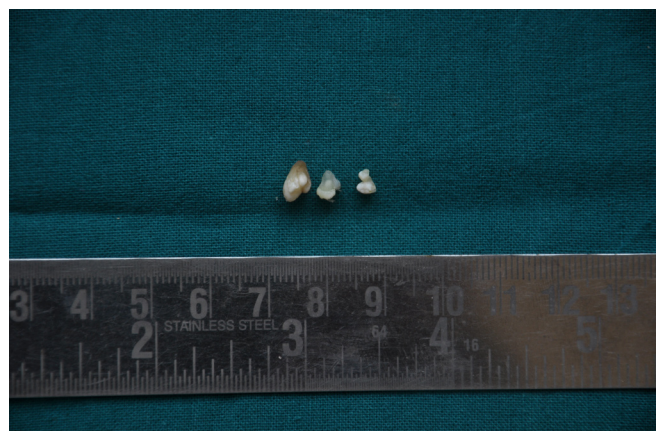

Figure 3 - Excised specimen

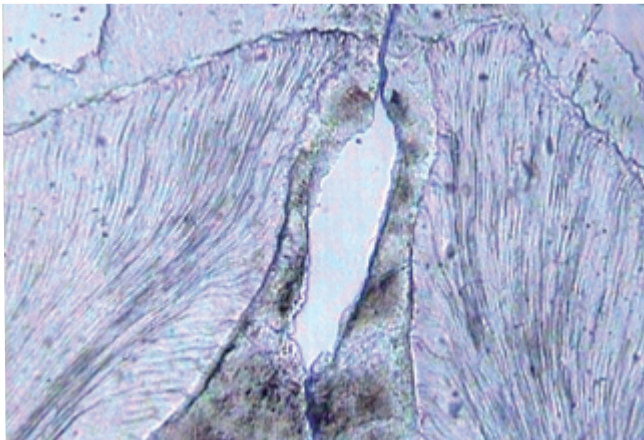


Figure 4 - Ground section showing tooth-like structure made up of enamel, dentin and cementum (20X)

Case report two

A twenty-seven year old male patient reported with a complaint of hard structure on the left side of jaw since one year. Past medical and dental history of the patient was not significant. Intraoral examination revealed four tooth-like structures, one located in the interdental region of 23 and 24, the rest were located apically on the gingiva in the same region. No significant changes were noted on the surrounding mucosa (figure 5). The structures were hard, non tender and mobile. Intraoral periapical radiograph revealed multiple structures of varying densities between 23 and 24 (figure 6). All the structures were surgically removed under local anaesthesia (figure 7). The extracted specimens were subjected to histopathological examination, which revealed enamel, dentin and cementum with pulp space. Tooth like arrangement of dental hard tissue confirmed the diagnosis of compound odontoma (figure 8).

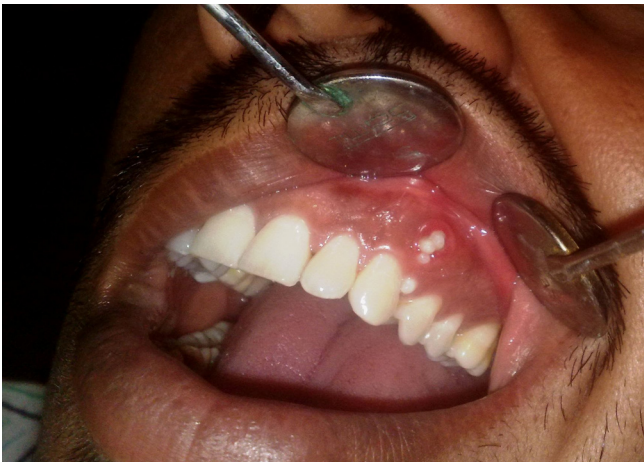

Figure 5 - Clinical photograph showing eruption of the denticles

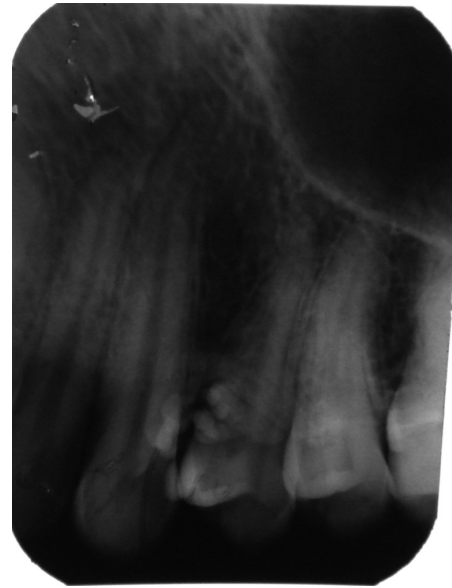

Figure 6 - IOPA radiograph showing structures of varying densities

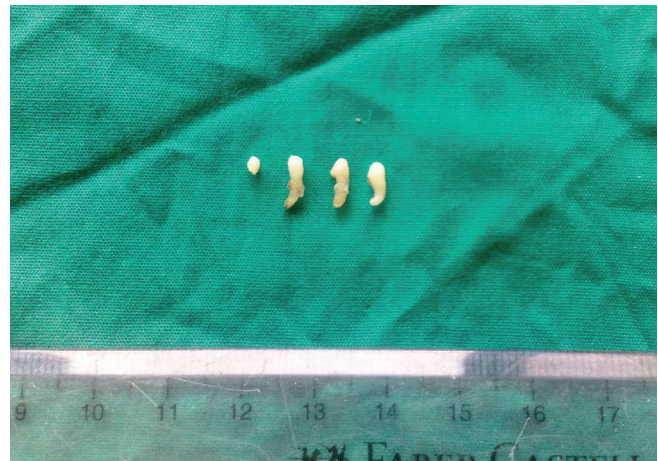


Figure 7 - Extracted surgical specimen

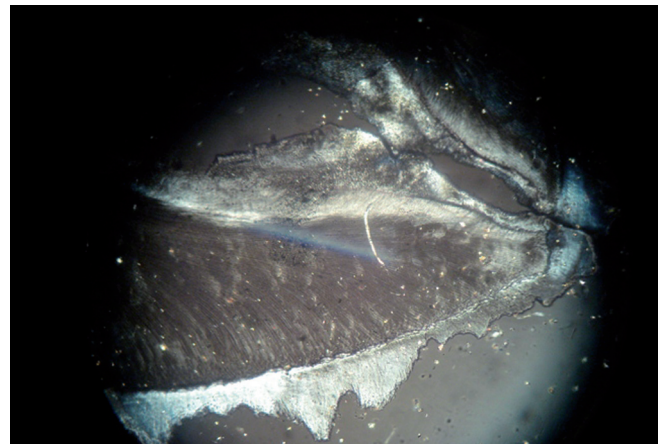


Figure 8 - Photomicrograph of ground section showing enamel rods, dentinal tubules and pulp space (10X)

Discussion

According to the histopathological perspective, odontomas can be grouped as: (a) complex odontomas, in which the dental tissues are well formed but exhibit a more or less disorderly arrangement; and (b) composite odontomas, in which the dental tissues are normal, but their size and conformation are altered giving rise to multiple small tooth-like structures called denticles [1]. The complex odontomas are usually located in the posterior mandible, while composite odontomas are more often found in the anterior maxilla [2]. There have been isolated reports of odontomas in the maxillary sinus [6]. An infrequent situation is when the odontoma has erupted, i.e., when it becomes exposed through the soft tissues. Rumel *et al.* [8] in 1980 described the first case of erupted odontoma. Since then only nine cases of erupted compound odontoma are reported in the literature [9]. In general, majority of these lesions are diagnosed in patients of less than 40 years of age. Complex odontoma are less common in comparison with compound variety at 1:2 ratio [10]. Majority of odontomas are asymptomatic and literature reports only few cases of swelling, delayed eruption and in severe cases, infection or lymphadenopathy [3]. In 70% of odontomas, pathological anomalies are observed in relation to the neighbouring teeth such as devitalisation, malformation, aplasia, malposition and impacted teeth [5]. None of our cases reported with any secondary symptoms associated with the odontoma. Compound odontoma is usually located between the apex of primary tooth and the crown of the permanent tooth preventing the eruption of latter [7]. However in both of our cases, the odontoma was located outside the jaw bone, in the soft tissue covering the tooth bearing portion of the jaw. The radiographic characteristics of odontomas are always diagnostic. The lesion consists of well defined radio-opacity surrounded by a radiolucent halo, which represents an enlarged cystic follicle. In compound odontoma multiple teeth like structures of varying size and shape are seen. Radiographically three different development stages can be identified depending on the degree of odontoma calcification. In the first stage, the lesion appears radiolucent due to the lack of calcification, intermediate stage is characterized by partial calcification; and in the final stage the odontoma appears radio-opaque which is surrounded by a radiolucent halo [10]. Since odontomas are well capsulated lesions and have less chances of recurrence, the

management comprises of conservative surgical excision. Histologically, odontomas comprise of varying amount of enamel, pulp tissue, enamel organ and cementum. The connective tissue capsule is similar to that of dental follicle. Ghost cells are often seen along with spherical dystrophic calcification, enamel concretions and sheets of dysplastic dentin [2].

Conclusion

This report constitutes two of the very few cases reported in the literature where odontomas erupt into the oral cavity and can be examined visually and manually. Since odontomas represent a large proportion of jaw tumors, adequate knowledge of their characteristics is necessary for establishment of proper diagnosis and management.

References

1. Barnes L, Eveson JW, Reichart P, Sidransky D (Eds.). World Health Organization Classification of Tumours. Pathology and genetics of E558 head and neck tumours. Lyon: Iarc Press; 2005. p. 310.
2. Cohen DM, Bhattacharyya I. Ameloblastic fibroma, ameloblastic fibro-odontoma, and odontoma. *Oral Maxillofacial Surg Clin N Am.* 2004 Aug;16(3):375-84.
3. Hidalgo-Sanchez O, Leco-Berrocal MI, Martinez-Gonzalez JM. Metaanalysis of the epidemiology and clinical manifestations of odontomas. *Med Oral Patol Oral Cir Bucal.* 2008 Nov;13(11):E730-4.
4. Junquera L, de Vicente JC, Roig P, Olay S, Rodriguez-Recio O. Intraosseous odontoma erupted into the oral cavity: an unusual pathology. *Med Oral Patol Oral Cir Bucal.* 2005 May-Jul;10(3):248-51.
5. Kaneko M, Fukuda M, Sano T, Ohnishi T, Hosokawa Y. Microradiographic and microscopic investigation of a rare case of complex odontoma. *Oral Surg Oral Med Oral Pathol Oral Radiol Endod.* 1998 Jul;86(1):131-4.
6. Mupparapu M, Singer SR, Rinaggio J. Complex odontoma of unusual size involving the maxillary sinus: report of a case and review of CT and histopathologic features. *Quintessence Int.* 2004 Sep;35(8):641-5.

7. Reichart PA, Philipsen HP. Complex odontoma. In: Odontogenic tumours and allied lesions. Chicago: Quintessence; 2004. p. 141-9.
8. Rumel A, de Freitas A, Birman E, Tannous L, Chacon P, Borkas S. Erupted complex odontoma. Report of a case. Dentomaxillofac Radiol. 1980;9:5-9.
9. Serra-Serra G, Berini-Aytes L, Gay-Escoda C. Erupted odontomas: a report of three cases and review of the literature. Med Oral Patol Oral Cir Bucal. 2009 Jun 1;14(6):E299-303.
10. Vengal M, Arora H, Ghosh S, Pai KM. Large erupting complex odontoma: a case report. J Can Dent Assoc. 2007 Mar;73:169-72.