

Original research article

Fixation of femoral fractures with titanium plate and screws: a pilot study in rats

Jennifer Tsi Gerber¹
Gabrielle Grosko Kuchar¹
Suyany Gabriely Weiss¹
Fernanda Tiboni¹
Luana Mordask Bonetto¹
Paola Fernanda Cotait Corso¹
Thaís Costa Casagrande^{2,3}
Rafaela Scariot⁴

Corresponding author:

Rafaela Scariot
Avenida Prefeito Lothario Meissner, 632 – Jardim Botânico
CEP 80210-170 – Curitiba – PR – Brazil
E-mail: rafaela_scariot@yahoo.com.br

¹ Universidade Positivo, School of Health Sciences – Curitiba – PR – Brazil.

² Universidade Positivo, Department of Industrial Biotechnology – Curitiba – PR – Brazil.

³ Universidade Positivo, Department of Veterinary Medicine – Curitiba – PR – Brazil.

⁴ Universidade Federal do Paraná, School of Dentistry, Department of Stomatology – Curitiba – PR – Brazil.

Received for publication: July 2, 2020. Accepted for publication: September 10, 2020.

Keywords:

bone regeneration;
femoral fractures;
fracture fixation;
fracture; femur;
Wistar rats.

Abstract

Introduction: The repair of bone defects is a study model that has been used in several experiments to analyze the influence of surgical and pharmacological approaches aiming to improve bone regeneration. Mechanical stimulus is a crucial factor in the healing process. Therefore, a variety of measures exists to aid in bone repair by using different methods of immobilization and fixation. **Objective:** To delineate an unprecedented technique of stable bone fixation with titanium plates and screws in rat femoral fracture. **Material and methods:** Six Wistar rats underwent surgical procedures for complete femur fracture and fixation with titanium plates and screws, in six different combinations. The rats were divided into two subgroups, according to the technique applied: fixation performed after the bone fracture, and fixation performed before fracture induction. The animals were euthanized 45 days after the procedure, and the femur was evaluated clinically and radiographically. **Results:** There was a failure of the fracture fixation in the majority of the animals, except in rat 6, which had a good stability of the bone stumps and satisfactory bone repair. **Conclusion:** The best technique was with a four-hole titanium plate and four screws of the 2-mm system, with the fixation of the material prior to fracture induction.

Introduction

Fracture repair is a complex biological process that follows specific regenerative patterns and involves many stages, such as cell recruitment to an injury site, cell proliferation, and differentiation of these cells [6]. Following the initial trauma, there are two ways of bone healing: direct intramembranous healing, and indirect fracture repair. The direct bone healing requires anatomical reduction and rigidly stable conditions, commonly obtained by internal fixation, which causes direct remodeling of the lamellar bone, Haversian canals, and blood vessels [23]. Under other conditions, indirect healing consists of both endochondral and intramembranous bone healing [8]. This type of healing does not require anatomical reduction or rigidly stable conditions, and it is characterized by the formation of bone callus [10].

Mechanical stimulus plays a fundamental role in the healing process of bone fractures [1]. Therefore, it is necessary the development of stable fixation techniques in animals to allow a better understanding of bone repair and its association with drugs and others. Since rats represent the ideal model to evaluate healing and bone regeneration [14], several studies have emerged in recent years to investigate repair mechanisms through femoral fractures in rats. Previous researches have been conducted using cerclage with Kirschner wire [3], internal fixation with a metallic clip [7], intramedullary fixation with stainless wire [25], intramedullary locking nail [21], external fixation [4, 20, 21], and a locking plate [11, 13, 19, 21] in an attempt to evaluate techniques that may influence bone healing of femoral fractures.

Despite titanium plates and screws being the most common forms of bone fixation in humans, their use in femoral fractures in animal models is restricted [24]. Previous studies have applied stable fixation, but there is no methodology defined for a study model using titanium plates and screws. Therefore, the aim of this research was to develop a surgical technique of stable fixation for femoral fracture in rats using titanium plates and screws, which may be applied in future investigations related to bone regeneration and similar areas.

Material and methods

Ethical aspects

The experiments were carried out at the vivarium of Universidade Positivo, after approval in the Animal Ethics Committee (ECUA 320).

Experimental design

Six male Wistar rats of 6 months old and weighing approximately 500 grams were used in the study. They were divided into six groups, using different fixation techniques at different times. They were also divided into two subgroups according to the technique applied: fixation performed after the bone fracture, and fixation performed before fracture induction. The animal protocol was designed to minimize pain or discomfort to the animals. Throughout the experimental period, the environmental conditions of light, temperature and humidity were controlled by a digital panel to maintain a photoperiod of 12 hours, the temperature range of 18-22°C and humidity of 65%.

Surgical procedure

The rats were sedated with isoflurane (Cristália, Itapira, SP, Brazil) and anesthetized with ketamine hydrochloride 10% (Vetbrands, Paulínia, SP, Brazil) and xylazine hydrochloride 2% solution (Vetbrands, Paulínia, SP, Brazil). After anesthesia, the animals were positioned in left lateral decubitus position, and the right femur trichotomy was performed with posterior antisepsis using iodopovidone. A straight 3-cm incision along the axis of the right femur was done with a #15 scalpel blade, and then division of the muscular planes was performed with Metzenbaum scissors until the total femur was exposed.

In rats 1, 2, and 3, a femoral fracture was performed in the central region with a reciprocating saw (NSK, Shinagawa, Tokyo, Japan) and constant irrigation, which was followed by fixation with titanium plates and screws (Figures 1A and 1B). However, in rats 4, 5, and 6, it was proposed to perform the fixation of the plate and screws before fracture induction, in order to obtain better stabilization of the bone stumps due to the difficulty experienced in positioning them during the fixation of the material after the fracture (Figures 1C and 1D).

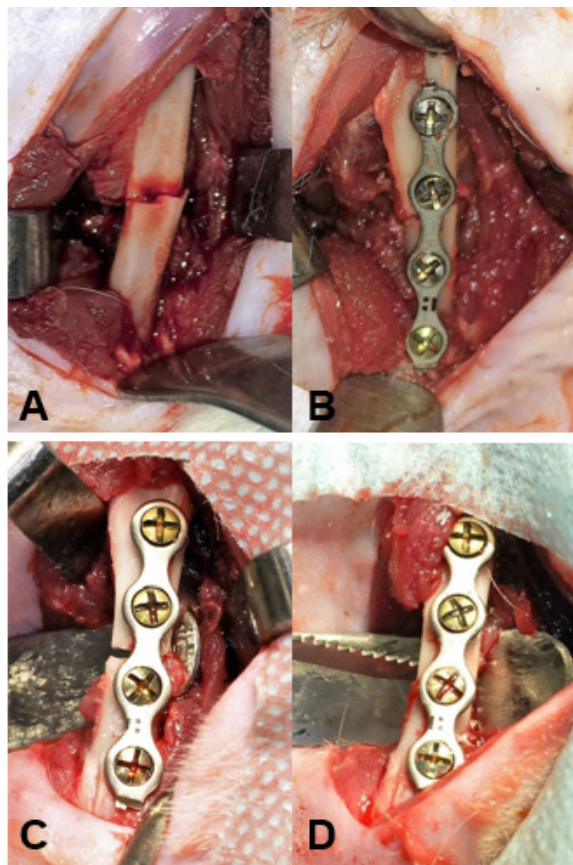


Figure 1 - Surgical procedure. (A) Osteotomy of the femur in the central region. (B) Fixation of plates and screws after the femur fracture. (C) Plate and screws fixated before bone fracture. (D) Osteotomy performed after bone fixation

All screws utilized in this study had 4-mm length, that is compatible with the diameter of the femur. The size of the plates and screws used in each group is presented in Table I.

Table I - Fixation performed in all groups*

Rat	Technique	Plate	Screw diameter (mm)
1	Fixation after fracture induction	Two holes 1.5 mm	1.5
2	Fixation after fracture induction	Two holes 2 mm	2
3	Fixation after fracture induction	Four holes 1.5 mm	1.5
4	Fixation prior fracture induction	Four holes 1.5 mm	1.5
5	Fixation prior fracture induction	Four holes 2 mm	1.5
6	Fixation prior fracture induction	Four holes 2 mm	2

*All screws had 4 mm of length

The incisions were sutured with simple stitches by planes. For suturing the muscles, 4-0 Vicryl sutures (Ethicon, Johnson & Johnson, São José dos Campos, SP, Brazil) were used, and for the cutaneous region 4-0 Nylon sutures (Ethicon, Johnson & Johnson, São José dos Campos, SP, Brazil) were used. In the postoperative period, tramadol hydrochloride (Pfizer, São Paulo, SP, Brazil) was administered intraperitoneally every 12 hours (7 mg/kg) for five days as an analgesic control agent. Ketoprofen (União Química Farmacêutica Nacional, Brasília, DF, Brazil) was used as an anti-inflammatory, administered intraperitoneally

(5 mg/kg) once a day for three days. For gastric protection of the rats, ranitidine hydrochloride (EMS, Taubaté, SP, Brazil) was orally administered (5 mg/kg) every 12 hours for three days. To prevent post-surgical infection, a common complication in orthopedic surgeries, enrofloxacin 2.5% (Chemitec, Ipiranga, SP, Brazil) was administered (10 mg/kg) once a day for seven days. In the postoperative period, the rats were stored in their own cages with food and water.

Radiographic evaluation

Seven days after the surgical procedure, the rats were sedated with isoflurane in order to perform the digital radiographs (Kodak x-ray sensor, Rochester, New York, United States), which were used to evaluate the position of the bone stumps, as well as the plates and screws. After the rats were euthanized and the plates and screws removed, another digital radiograph was performed, to observe the bone repair in the fracture site (Figures 2A and 2B).

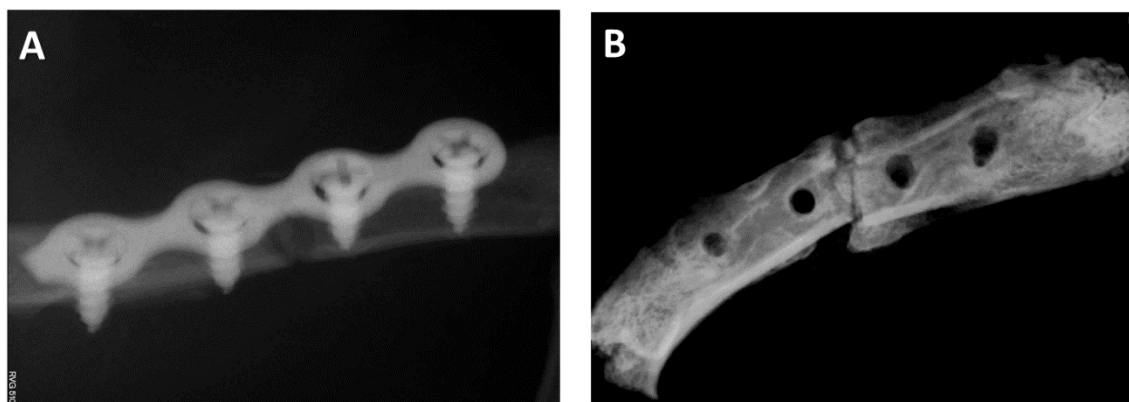


Figure 2 - Postoperative radiographs: (A) seven days from the procedure; (B) 45 days from the procedure

Euthanasia

Forty-five days after the surgical procedure, the rats were euthanized in a gas chamber of CO₂ for 10 minutes. The femurs were harvested and clinically evaluated.

Clinical analysis

At the time of clinical evaluation, the success of the technique was dependent upon the position of the plates and screws, such that there were no deformations present. Then, the material fixation was removed to observe if there were any displacement of the stumps, any absence of bone reabsorption and to ensure appropriate bone healing.

Results

The results obtained from the applied techniques in all groups are represented in Table II.

Table II - Results from the applied techniques

Rat	Technique	Fixation material	Radiographic evaluation (7 days)	Radiographic evaluation (45 days)	Clinical analysis
1	Fixation after fracture induction	Two holes plate and screws (1.5 mm)	Plate and screws displacement	-	-
2	Fixation after fracture induction	Two holes plate and screws (2 mm)	Plate and screws displacement	-	-

Continue...

Continuation of the table II

Rat	Technique	Fixation material	Radiographic evaluation (7 days)	Radiographic evaluation (45 days)	Clinical analysis
3	Fixation after fracture induction	Four holes plate and screws (1.5 mm)	Infection in the fracture site	-	-
4	Fixation prior fracture induction	Four holes plate and screws (1.5 mm)	Fracture displacement and plate deformation	-	-
5	Fixation prior fracture induction	Four holes plate (2 mm) and screws (1.5 mm)	Stability of the fracture site and the fixation material	Stability of the fracture site and the fixation material	Absence of stability in the screws and in the fracture repair
6	Fixation prior fracture induction	Four holes plate and screws (2 mm)	Stability of the fracture site and the fixation material	Stability of the fracture site and the fixation material	Satisfactory bone repair with presence of bone callus

The best applied technique was with fixation of the material prior to fracture induction, which had better stabilization of the bone stumps during the surgery. In addition, the best material used was the four-hole titanium plate of 2-mm system, and four screws 2-mm thick and 4-mm long. The use of these plate and screws showed satisfactory bone repair and the presence of bone callus.

Discussion

Most studies of femur fractures in rats utilized unstable fixation techniques where bone fractures were left without full stabilization of the stumps, compromising the result of effective bone healing [4, 16, 22]. Some studies describe the use of internal femoral fixation with cerclage of the stumps with Kirschner wire [3], external fixator [4] and pin-clip [7].

In some studies, the unstable fixation technique was associated with the formation of pronounced bone callus and a delay in the fracture healing process, whereas the stable fixation technique was associated with the formation of reduced bone callus and an accelerated healing process [5, 12]. Garcia *et al.* reported that a decrease in inter-fragmentary movement of the fracture increases the percentage of bone in the callus tissue. They also found an increased proportion of fibrous tissue with the use of the unstable fixation technique [7]. Another study

performed on sheep tibia using the stable fixation technique observed that the decreased formation of fibrous tissue and increased bone formation were associated with increased angiogenesis and expansion of mesenchymal stem cells [17]. Therefore, these studies demonstrate that inter-fragmentary movements affect fracture healing and tissue differentiation. Also, a stable fixation technique promotes angiogenesis stimulation and the expansion of stem cells, proving that fracture stability is the main factor in efficient bone repair [15].

Conventional titanium plates and screws are designed to promote fracture stability, because they resist to axial, bending, and rotational forces, and their use is the only method that allows immediate postoperative mobility. Also, this material has mechanical features very similar to the bone ones, leading to an adequate three-dimensional stability for bone healing [2]. Plates and screws are highly employed in human medicine and dentistry, and they are the first choice when total stabilization is needed in fractures of the oral and maxillofacial complex [9]. Therefore, in the present study, the rationale for the use of this fixation material was to seek a more stable method for the immobilization of fractures in the rat's femur, which leads to a more efficient bone healing. Additionally, it is important to develop techniques that can be replicable in humans, as animal models are used to understand the biological mechanism prior to clinical trials.

Within the limitations of this study, it is important to emphasize that the animal is constantly moving and supporting its hind paws. Therefore, it was not possible to immobilize the rats in the postoperative period during bone consolidation. Also, precise surgical techniques were used due to the small size of the rats. Another point to be addressed is that the fracture site had formation of a bone callus, which is an indicative of indirect bone healing, despite the use of the stable material. This may have occurred due to the movements exerted by the animal after the surgery, allowing for small inter-fragmentary movement of the stumps. Furthermore, it is relevant to consider that the plates and screws utilized in this study were not properly designed for the rat's femur or its anatomy. So, there were several muscular forces acting against the plates and screws when the rat was moving.

Compared with the techniques of unstable fixation, this new method may help understand the biologic processes of fracture healing and allow the development of therapeutic measures to accelerate the repair process. This new technique proved to be efficient for fracture fixation as it allowed adequate bone healing and formation of a bone callus. Although this callus does not have the same resistance as a bone, it is able to prevent the fracture site from being displaced, and this ensures that it will be replaced by a compact bone and, thenceforth, go through the process of bone remodeling [18].

Conclusion

In summary, the technique of employing the four-hole plate and screws of the 2-mm system demonstrated to be an efficient method for femoral fractures fixation in rats. This fixation technique is a useful model for future researches and may help provide new lines of treatment for fracture healing. However, further studies are required to evaluate this new technique in terms of bone repair and the development of therapeutic measures that accelerate bone formation.

References

Augat P, Simon U, Liedert A, Claes L. Mechanics and mechano-biology of fracture healing in normal and osteoporotic bone. *Osteoporos Int.* 2005 Mar;16(Suppl. 2):S36-43.

Boudrieau RJ, Kudisch M. Miniplate fixation for repair of mandibular and maxillary fractures in 15 dogs and 3 cats. *Vet Surg.* 1996;25(4):277-91.

Butezloff MM, Zamarioli A, Leoni GB, Sousa-Neto MD, Volpon JB. Whole-body vibration improves fracture healing and bone quality in rats with ovariectomy-induced osteoporosis. *Acta Cir Bras.* 2015 Nov;30(11):727-35.

Colnot C, Thompson Z, Miclau T, Werb Z, Helms JA. Altered fracture repair in the absence of MMP9. *Development.* 2003 Sep;130(17):4123-33.

Cullinane DM, Fredrick A, Eisenberg SR, Pacicca D, Elman MV, Lee C, et al. Induction of a neoarthrosis by precisely controlled motion in an experimental mid-femoral defect. *J Orthop Res.* 2002 May;20(3):579-86.

Einhorn TA. The science of fracture healing. *J Orthop Trauma.* 2005;19(10 Suppl.):S4-6.

Garcia P, Holstein JH, Histing T, Burkhardt M, Culemann U, Pizanis A, et al. A new technique for internal fixation of femoral fractures in mice: impact of stability on fracture healing. *J Biomech.* 2008;41(8):1689-96.

Gerstenfeld LC, Alkhiary YM, Krall EA, Nicholls FH, Stapleton SN, Fitch JL, et al. Three-dimensional reconstruction of fracture callus morphogenesis. *J Histochem Cytochem.* 2006 Nov;54(11):1215-28.

Gomes C, Gouvêa AS, Alievi MM, Contesini EA, Pippi NL. Titanium miniplates in mandibular fracture repair in dogs and cats: study of 6 cases. *Ciência Rural.* 2010;40:1128-33.

Green E, Lubahn JD, Evans J. Risk factors treatment, and outcomes associated with nonunion of the midshaft humerus fracture. *J Surg Orthop Adv.* 2005;14(2):64-72.

Gröngröft I, Heil P, Matthys R, Lezuo P, Tami A, Perren S, et al. Fixation compliance in a mouse osteotomy model induces two different processes of bone healing but does not lead to delayed union. *J Biomech.* 2009 Sep;42(13):2089-96.

Grundnes O, Reikeras O. Effects of instability on bone healing. Femoral osteotomies studied in rats. *Acta Orthop Scand.* 1993 Feb;64(1):55-8.

- Holstein JH, Garcia P, Histing T, Kristen A, Scheuer C, Menger MD, et al. Advances in the establishment of defined mouse models for the study of fracture healing and bone regeneration. *J Orthop Trauma.* 2009;23(5 Suppl.):S31-8.
- Jacenko O, Olsen BR. Transgenic mouse models in studies of skeletal disorders. *J Rheumatol Suppl.* 1995 Feb;43:39-41.
- Kampschulte M, Krombach GA, Richards DC, Sender J, Lips KS, Thormann U, et al. Neovascularization of osteoporotic metaphyseal bone defects: a morphometric micro-CT study. *Microvasc Res.* 2016 May;105:7-14.
- Le AX, Miclau T, Hu D, Helms JA. Molecular aspects of healing in stabilized and non-stabilized fractures. *Orthop Res.* 2001 Jan;19(1):78-84.
- Lienau J, Schell H, Epari DR, Schütze N, Jakob F, Duda GN, et al. CYR61 (CCN1) protein expression during fracture healing in an ovine tibial model and its relation to the mechanical fixation stability. *J Orthop Res.* 2006 Feb;24(2):254-62.
- Marsell R, Einhorn TA. The biology of fracture healing. *Injury.* 2011 Jun;42(6):551-5.
- Matthys R, Perren SM. Internal fixator for use in the mouse. *Injury.* 2009 Nov;40(Suppl. 4):S103-9.
- Meeson R, Sanghani-Keri A, Coathup M, Blunn G. VEGF with AMD3100 Endogenously Mobilizes Mesenchymal Stem Cells and Improves Fracture Healing. *J Orthop Res.* 2019 Jun;37(6):1294-302.
- Meyers N, Sukopp M, Jäger R, Steiner M, Matthys R, Lapatki B, et al. Characterization of interfragmentary motion associated with common osteosynthesis devices for rat fracture healing studies. *PLoS One.* 2017 Apr;12(4):e0176735.
- Opolka A, Ratzinger S, Schubert T, Spiegel HU, Grifka J, Bruckner P, et al. Collagen IX is indispensable for timely maturation of cartilage during fracture repair in mice. *Matrix Biol.* 2007 Mar;26(2):85-95.
- Rahn BA. Bone healing: histological and physiologic concepts. In: Fackelman GE, editor. *Bone in clinical orthopedics.* Stuttgart: Thieme; 2002. p. 287-326.
- Thormann U, El Khawassna T, Ray S, Duerselen L, Kampschulte M, Lips K, et al. Differences of bone healing in metaphyseal defect fractures between osteoporotic and physiological bone in rats. *Injury.* 2014 Mar;45(3):487-93.
- Vashghani Farahani MM, Masteri Farahani R, Mostafavinia A, Abbasian MR, Pouriran R, Noruzian M, et al. Effect of Pentoxifylline Administration on an Experimental Rat Model of Femur Fracture Healing With Intramedullary Fixation. *Iran Red Crescent Med J.* 2015 Dec;17(12):e29513.